The New England
Journal of Medicine

Copyright, 1955, by the Massachusetts Medical Society

Volume 253 AUGUST 11, 1955 Number 6

SEVERE PULMONARY DISEASE SUBSEQUENT TO ZENKER'S DIVERTICULUM

LLOYD E. HAWES, M.D.,* AND JAMES H. WALKER, M.D.†

BOSTON, MASSACHUSETTS, AND CHARLESTON, WEST VIRGINIA

IN any case of pulmonary disease of obscure origin an x-ray examination of the esophagus with barium may demonstrate some disease of the esophagus that causes regurgitation of food and saliva into the trachea. The cases of advanced pulmonary lesions reported below emphasize the importance of an esophageal examination since a Zenker diverticulum was easily demonstrated in each. Suppurative and lipoid pneumonia resulted from spillage of material from the high esophageal diverticulum into the trachea. In Case 1 an emergency closure of the diverticulum during convalescence from a lobectomy was necessary. The other patient (Case 2) died from a fulminating suppurative (lipoid) pneumonia, and though he had been studied for five years, the importance of a large Zenker diverticulum was not recognized until a few days before death.

Both cases illustrate the importance of correction of a high esophageal diverticulum rather than any direct attack on the pulmonary lesion. In addition lobectomy in the presence of a Zenker diverticulum in both cases was greatly hampered by large amounts of secretion that continued spilling into the trachea during operation. The spilled fluid was a definite handicap to the anesthetist.

CASE REPORTS

CASE 1. A 62-year-old woman, during a routine physical checkup, was found to have a dense area of consolidation (Fig. 1) in the medial portion of the base of the right lung. She denied any pulmonary or other symptoms and produced no sputum. During fluoroscopy of the chest a small, high esophageal (Zenker) diverticulum was discovered (Fig. 2). Two bronchoscopies were accomplished without revealing any abnormality of the bronchial tree.

Physical examination revealed a well developed and well nourished woman. A well healed thyroidectomy scar (from an operation 25 years previously) was present, and a small portion of thyroid gland was palpable on the right side. No definitely palpable cervical lymph nodes were found. Examination of the chest showed an occasional fine rale at the base of the right axilla. Laboratory data, including blood sugar and nonprotein nitrogen, were normal. Examinations of the sputum for tubercle bacilli were negative. Many sputum examinations were performed for tumor cells, and 1 was reported as showing atypical cells.

Two months after the initial discovery of the lesion exploratory thoracotomy revealed the right middle and the anterior and medial basal segments of the right lower lobe to be completely solid and very firm. They had the feeling of a malignant process, and a few nodes in the interlobar fissures were of the same consistence. One submitted for frozen section showed only evidence of chronic inflammation. The right lower and middle lobes were resected without difficulty.

The postoperative course was marked by the accumulation of large amounts of secretions in the bronchial system, requiring several bronchoscopies and frequent intratracheal aspirations. It was decided that these had accumulated and spilled from the Zenker diverticulum. An emergency inversion and later incision of the sac had to be done. The secretions were thereby controlled.

Pathological examination of the lung showed gray-tan areas of consolidation, primarily in the dependent portions of the lobe, measuring up to 4.5 cm. The bronchi in the middle lobe were not remarkable, but those in the lower lobe were thickened and dilated, with cross-striations. The cytologic diagnosis was lipoid pneumonia.

This patient, with a preoperative presumptive diagnosis of lung tumor, was known to have a Zenker diverticulum before the resection. Its importance was not recognized. During convalescence from the lobectomy while she was inactive in bed, the secretions from the diverticulum were embarrassing and caused difficulty in breathing and coughing. An emergency second and later a third operation, while she was recuperating from the lobectomy, were necessary to give symptomatic relief.

CASE 2. A 52-year-old man had had a cough with purulent sputum for many years. Five years before the final admission he had a frank pneumonia of the left upper lobe (Fig. 3). At that time he had an increase in cough, a temperature between 99 and 100.5° F., profuse sweating, some dyspnea, but a normal white-cell count (8300 to 5000). Examination of the sputum revealed a mixed flora and no tubercle bacilli. Resolution was rapid under chemotherapy, but the lesion had not cleared entirely when the patient was discharged. However, the cough and fever had disappeared. The discharge diagnosis was atypical pneumonia. When he returned to work, the cough reappeared. On two occasions he had to be hospitalized because of an increase in cough. Four years before the final admission he had a 2d attack of pneumonia in the left upper lobe and was hospitalized for 6 days. Examinations of the sputum for tubercle bacilli were negative. He raised 60 cc. of thick, white sputum daily.

Two years before the final admission, because of increase in cough and weight loss, he was admitted for resection

*Radiologist, Faulkner Hospital; consultant in radiology, Veterans Administration hospitals, Boston and West Roxbury, Massachusetts.

†Special lecturer on diseases of the chest, West Virginia University School of Medicine, Morgantown, West Virginia; chief of thoracic surgery, Charleston Memorial Hospital; thoracic surgeon, Hopemont Sanatorium, Hopemont, West Virginia.

of the left upper lobe. Physical examination revealed a tall, slender man who appeared older than his stated age and had evidence of marked weight loss. The chest was long and slender but symmetrical; in the left upper portion the percussion note was greatly impaired, and moist rales were present. Bronchoscopy demonstrated a slight diminution in the caliber of the left-upper-lobe bronchus. No tumor cells or tubercle bacilli were found in the aspiration material. An exploratory thoracotomy was performed. During

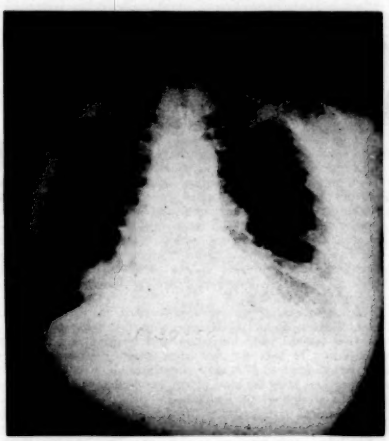

FIGURE 1. *Rounded, Hazy Area of Increased Density in the Right Cardiophrenic Angle (Asymptomatic) in Case 1.*

the administration of topical cocaine for tracheal intubation, the patient coughed up about half a sputum box of mucopurulent, watery material. When the left pleural space was opened no free fluid was found, but there were dense inflammatory adhesions binding the apex to the posterior mediastinum. The upper lobe was retracted, and firm, nodular areas extended throughout. There was a dense inflammatory reaction with some fibrosis around the hilus of the left upper lobe. The lower lobe appeared to be uninvolved except for superficial nodulation in the vertebral subsegment of the superior division. After resection the patient had difficulty in raising bronchial secretions, and it was necessary to employ intratracheal aspirations on many occasions. At the time of discharge from the hospital he still had a small cap of air at the apex, with a fluid level. One month later he reported no cough or expectoration and thought that he was improving steadily.

Pathological examination of the left upper lobe showed a dark-gray, irregularly roughened pleura and an irregularly firm parenchyma. On section numerous areas of pale-yellow-gray, firm tissue were observed; some of these were poorly defined. Occasionally, there were subpleural blebs. The bronchi in the region of the hilus had moderately thickened walls, with irregular thickening of the mucosa. More peripherally the bronchial mucosa was thin walled and transversely wrinkled, with slight dilatation of the lumen. No definite abscesses were identified, and no tumor was found. The cytologic diagnosis was chronic pneumonitis with fibrosis and numerous lipophages that suggested to the pathologist an organizing pneumonia rather than a lipoid pneumonia.

Two months after the resection the patient reported that he was free from cough and had no sputum.

Five days before the final admission to the Boston Veterans Administration Hospital he became weak, sweated profusely and had a severe cough. On admission he was acutely and chronically ill, cachectic and breathing rapidly and shallowly and was poorly oriented. There was slight clubbing of the fingers and slight cyanosis. Examination of the chest showed dullness on the left, with vocal fremitus, decrease in tactile fremitus, rales and gurgles. The white-cell count, initially 7000, rose in a few days to 19,750 and 22,800. There was no anemia. The temperature was 102° F., and it never fell below 101°F. during the hospital stay; the pyrexia was not swinging, but steady.

X-ray studies (Fig. 4) showed the left hemithorax to be filled with large and small cavities, some with fluid levels in them. The left leaf of the diaphragm was slightly elevated. For the 1st time in over 5 years in and out of various hospitals a barium swallow was given, revealing a huge (10-cm.) Zenker diverticulum (Fig. 5) that descended into the superior mediastinum in the midline. The barium was trapped in it for several minutes, and some barium spilled into the trachea and into the bronchi during the examination. Esophagoscopy was impossible since the diverticulum actually obliterated the esophageal lumen.*

The patient regurgitated all food and liquid. A tracheotomy was performed to allow aspiration of the large amounts of secretion. Intravenous injections of oxytetracycline were given, as well as penicillin and streptomycin, without result. He died on the 12th hospital day.

Autopsy revealed a well developed, slightly emaciated man with a midline tracheotomy incision above the su-

FIGURE 2. *Barium-Filled Zenker Diverticulum (Case 1), Extending down behind the Cervical Esophagus and Measuring 15 Mm. in Diameter.*

prasternal notch. The left pleural cavity was completely obliterated by fibrous adhesions and was filled by the lower lobe. In the lobe there was a large abscess cavity, 20 by 10 by 6 cm., which contained air and pus and was lined by necrotic tissue. Numerous small abscesses were also present in the upper portion of this lobe. The bronchi contained yellow-pink pus and showed an injected, deeply reddish mucosa. The right lung had a smooth pleural surface. The upper lobe was pinkish purple and exuded yellow pus from injected bronchi. The upper lobe contained many small cavities, 7 mm. to 2 mm. in diameter. There was a large pulsion diverticulum of the esophagus

*Ross[1] also reports a case of complete obliteration of the esophagus by a large Zenker diverticulum.

lying posteriorly and just below the larynx. It measured 7 cm. in length and 6 cm. in diameter. Its wall was 3 mm. thick. No other diverticula were found in the gastrointestinal tract.

Microscopical examination of the left lung showed many areas of fibrous organization, small abscesses and alveoli filled with exudate. This exudate consisted of macrophages, leukocytes and occasional foreign-body giant cells. In the right lung the exudate was similar, and several small patchy areas of atelectasis and emphysema were present.

A large Zenker diverticulum was not recognized as the cause of the patient's pulmonary disease until it was too late to remove it or to treat the extensive suppurative pneumonia. He had had an upper-lobe resection, followed in two years by the same destructive suppurative pneumonia throughout the remaining lower lobe. The disease was localized on x-ray examination to the left side, but it was found that he slept on this side, and his secretions therefore flowed into

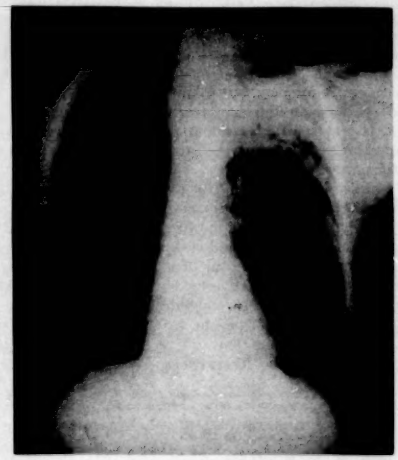

FIGURE 3. *Soft, Patchy Pneumonia in the Left Upper Lobe in Case 1 (March, 1948).*

that side when he was asleep. On post-mortem examination, however, pinpoint abscesses were also found in the opposite lung.

Lipoid and suppurative pneumonia arising from the ingestion of oils such as mineral oil and cream is well known in both children and adults. The pulmonary lesions may be single, resembling lung tumor, or may be multiple and abscessed. They are often chronic and recurrent, and bronchiectasis may develop. A smaller group of cases of lipoid pneumonia result from lesions in the esophagus. These include achalasia or cardiospasm, Zenker's diverticulum, other esophageal diverticula,[2] benign or malignant strictures of the esophagus and traumatic perforating or malignant lesions. In this group the esophageal disease is the primary factor, and no cure can be accomplished by medical therapy or surgical resection of the pulmonary disease. Of all these causes Zenker's diverticulum

FIGURE 4. *Extensive Cavitating Pneumonia throughout the Remaining Left Lower Lobe in Case 2 Five and a Half Years after the Initial Attack (Fig. 3). Note the barium in the right bronchial tree.*

is amenable to complete surgical removal; Lahey and Warren[3] recently reviewed their success in 250 cases.

FIGURE 5. *Anteroposterior Spot Film, Showing the 7-Cm., Barium-Filled, Centrally Placed Zenker Diverticulum.*

Aspiration from Zenker's diverticulum usually occurs when the patient is recumbent.[4] Often, the pa-

tient is awakened by flooding of liquid material into his throat; he coughs and chokes with it. Some of the material descends through the trachea into the lungs. The insult to the lung tissue is repeated many times, and areas of pneumonitis develop from plugging of minor bronchi and reaction to the foreign material. The resulting lung disease (as in Case 2) may have periods of superimposed infection or pneumonia when aerobic and anaerobic, virulent organisms infect the area of disease.

The presence of a Zenker diverticulum, as in Case 1, is a hazard to any patient who must be given an anesthetic by mouth. The collection and spillage of secretions during anesthesia will make repeated aspirations necessary throughout the operation. In thoracic surgery, with intratracheal anesthesia, the secretions can be annoying, for a clean, dry trachea is necessary for a considerable length of time.

Discussion

A Zenker diverticulum is a hazard to patients confined to bed during convalescence from surgery or from any disease. Such patients are less able to cope with the regurgitation of fluid into the throat when unconscious or asleep, and severe paroxysms of coughing and choking may ensue. In Case 1 convalescence from lobectomy could not be accomplished until two operations for inversion and removal of a diverticulum had been carried out; it was believed incorrectly that a small diverticulum — not over 3 cm. in diameter — was probably only of academic interest.

The cause of the Zenker diverticulum itself is believed to be protrusion of the esophageal mucosa through a weak point in the esophageal wall posteriorly just below the pharyngeal esophageal opening.[5] A sac protrudes into the soft tissues posteriorly, usually at the level of the third and fourth cervical segments, and as it enlarges the sac must seek more room by turning laterally into the soft tissues. The sac is now just above or behind the thyroid gland. The patient may recognize the mass in the neck and realizes that it enlarges with swallowing and can be reduced manually. Brintnall and Kridelbaugh[6] described 2 infants with congenital diverticula in this area; both died with bilateral lower-lobe pneumonia in spite of operation.

One of us (L.E.H.) had a patient who had had a hemithyroidectomy performed to remove a mass in the anterior portion of the lower neck lateral to the trachea. He was discharged but shortly afterward returned to his doctor complaining of recurrence of the mass. For the first time a barium-swallow examination was performed, and a Zenker diverticulum was found. The palpable mass disappeared when the diverticulum was removed. In Case 1 the relation of the diverticulum to the thyroidectomy twenty-five years previously is interesting. Does a thyroidectomy increase the tendency for a Zenker diverticulum to form by weakening the soft tissues around the cervical esophagus?

Conclusions

Before any operation on a pulmonary lesion of unknown etiology the absence of primary esophageal disease must be ascertained by fluoroscopy with barium. A primary malignant process, with or without perforation into the trachea or bronchial tree, esophageal stricture, achalasia and diverticula, may be associated with severe chronic and recurrent pulmonary disease.

Zenker's diverticulum not only may lead to lipoid pneumonia with bronchiectasis and suppurative pneumonia but also is a definite hazard during inhalation anesthesia and to any bed-ridden, inactive patient.

The emergency removal of a Zenker diverticulum may be necessary in any convalescent patient who is embarrassed by severe coughing and choking from the material spilling from the sac.

References

1. Rose, T. F. Pharyngeal diverticulum: report of large diverticulum causing complete obstruction to oesophagus. *M. J. Australia* **2**: 776-779, 1951.
2. Katz, H. I. Traction diverticula of esophagus in middle lobe syndrome. *Am. Rev. Tuberc.* **68**:455-464, 1952.
3. Lahey, F. H., and Warren, K. W. Esophageal diverticula. *Surg., Gynec. & Obst.* **98**:1-28, 1954.
4. Lahey, F. H. Pharyngo-esophageal diverticulum: its management and complications. *Ann. Surg.* **124**:617-636, 1946.
5. Johnstone, A. S. Symposium: diverticula of alimentary tract: diverticula of oesophagus. *Brit. J. Radiol.* **22**:415-422, 1949.
6. Brintnall, E. S., and Kridelbaugh, W. W. Congenital diverticulum of posterior hypopharynx simulating stenosis of esophagus. *Ann. Surg.* **131**:564-574, 1950.

SPECIFIC THERAPY FOR SALICYLISM*

GEORGE E. SCHREINER, M.D.,† LEONARD B. BERMAN, M.D.,‡ JOHN GRIFFIN, M.D.,§ AND JEAN FEYS, M.D.¶

WASHINGTON, D. C.

SALICYLATES account for 4 per cent of all the fatal poisonings in the United States[1] due to solids and liquids. Mortality statistics include all forms of the drug since the toxic effects depend on the salicylate radical. Although fatal cases have been reported in adults with as little as 2 gm. of aspirin[2] the more usual lethal dose is in excess of 10 gm.[3] Deaths from 0.3 gm.[4] may be dismissed from the present discussion as hypersensitivity phenomena usually occurring in asthmatic patients.

The major clinical manifestations of salicylate poisoning have been well described,[5] as have many of the complications. These include disturbances of acid-base balance,[6] bleeding tendencies,[1,7] brain damage,[8-10] renal changes[2] and gastric ulceration.[11,12] Despite these contributions, basic data are lacking in several aspects of the problem. Correlation of blood levels with clinical states, although fairly well documented for minor degrees of salicylism,[5] is largely nonexistent for fatal or nearly fatal poisoning, possibly because of the relatively late development of methods for estimating salicylates in blood and other tissues.[13,14] Reports of dosages in fatal cases are frequently open to question on grounds of unreliable history, dependence on indirect evidence such as empty bottles, and errors due to unmeasured losses from vomiting, gastric lavage, renal excretion and metabolism. The distribution of drug in the body and extent of plasma-protein binding have been studied to some extent[15] but are not yet well defined.

On a clinical level the greatest deficiency has been the absence of a specific method of treatment. Just as with any exogenous poison, treatment must be able to neutralize the toxin or remove it at a significantly greater rate than normal body processes. The possibility of removal of salicylates at such a rate is now an established reality. As early as 1913 Abel, Rowntree and Turner[16] demonstrated the dialysis of salicylate from the blood of animals with the use of celloidin tubes. The first attempt at dialysis in human beings was that of Doolan et al.[17] in 1951. These investigators, using a modified Kolff artificial kidney,[18,19] dialyzed a poisoned man who was comatose with a blood salicylate level of 55 mg. per 100 cc. The procedure was terminated because of technical difficulties at the end of an hour, during which 1.3 gm. of salicylate was removed without much change in the clinical state. The patient died a few hours later. The brain, in this case, showed changes that merit detailed description:

> The sections reveal slight fibrous thickening of the leptomeninges and mild arteriolar thickening, both of long standing. The acute processes consist of vascular changes and changes in the ganglion cells. The vascular changes include marked venous engorgement with perivascular hemorrhages extending into the tissue and beyond the confines of the perivascular space. The capillaries are dilated and congested without evidence of new capillary formation. The cellular changes suggest anoxia with shrunken neurons and attenuated, tortuous apical dendrites. The cytoplasm is poorly stained, there is very little Nissl substance most of which is distributed peripherally. The nuclei are shrunken and displaced and many of the cells are shadow cells, the nucleus having been extruded. There are no focal changes evident. The diagnosis is anoxic ganglion cell disease, venous congestion with scattered perivascular hemorrhages, old fibrous thickening of the leptomeninges, and mild arteriolar sclerosis.[8]

The occurrence of brain damage is similarly stressed in other reports.[9,10] The possibility of such changes emphasizes the need for *rapid* removal of salicylate from the body.

The present paper concerns studies carried out on 2 patients poisoned with aspirin, 1 of whom represents the first successful application of hemodialysis to salicylate poisoning in human beings.

MATERIALS AND METHODS

The patients, a man and a woman, were admitted to the Medical Service of Georgetown University Hospital for the treatment of aspirin poisoning.

All dialyses, clinical and experimental, were performed on a modified Kolff artificial kidney.[18,19] In vitro dialyses were carried out on solutions of salicylic acid in plasma and in saline solution using the Kolff machine with operating conditions similar to those in Case 1. Salicylate levels on serum, urine and dialysis bath were determined by the method of Keller,[14] which measures both free and conjugated salicylates. In our hands this method yields recoveries of 101 to 105 per cent. Qualitative salicylate tests on the urine were performed by the addition of 10 per cent ferric chloride to urine. A positive test is denoted by the prompt development of a purple color. Two precautions should be observed: acetone may produce a false-positive reaction, so that urine containing acetone should be boiled before testing; and phosphates may produce a false-negative reaction, with the precipitation of ferric phosphate. The addition of more reagent brings out a positive test.

All other determinations were done by standard laboratory methods.

*From the Department of Medicine, Georgetown University Hospital.
†Instructor in medicine, Georgetown University School of Medicine; director, Renal Clinic, Georgetown University Hospital.
‡Trainee, National Heart Institute; fellow in medicine, Georgetown University Hospital.
§Resident in medicine, Georgetown University Hospital.
¶Junior assistant resident in medicine, Georgetown University Hospital.

Case Reports

Case 1. A comatose 44-year-old man was admitted to Georgetown University Hospital at 1:00 p.m. on September 2, 1954. He had been found unconscious in his room at 5:30 that morning with 7 empty aspirin bottles, which represented a total of 210 gm. of aspirin. No further history was obtained on admission. His record showed 2 previous admissions to this hospital. At the 1st admission, which was in 1948 for epigastric pain, his work-up, including a gastrointestinal series, was negative, and he was discharged with

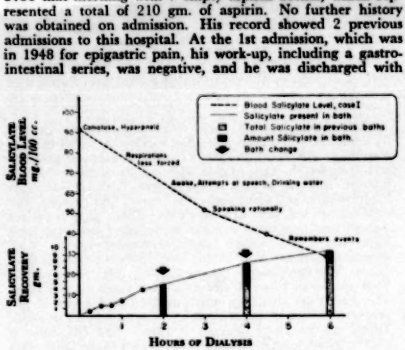

Figure 1. *Clinical Dialysis of Salicylate (Case 1).*

a diagnosis of gastritis. The 2d admission was in 1951 for the same complaint; gastrointestinal series were again negative. Additional diagnoses at this time were acne rosacea and anxiety reaction diagnosed by the psychiatric consultant. The question of alcoholism was raised but not settled at that time.

Physical examination on the present admission revealed a well developed, well nourished man who was comatose and grimacing slightly on painful stimuli. Other significant findings included a pustular erythematous rash over the face and chest, and absent corneal reflexes. The deep tendon reflexes were present and active. The Chvostek and Trousseau signs were absent.

The temperature was 104°F. by rectum, the pulse 120, and the respirations 22 and deep and regular. The blood pressure was 120/75.

Initial laboratory work showed a hematocrit of 50 per cent and a white-cell count of 12,950, with 93 per cent neutrophils. The urine was clear yellow, with a pH of 5.5 and a specific gravity of 1.018, and gave a + test for albumin, a negative test for sugar and a ++++ test for acetone. The sediment contained a rare white blood cell. The nitroprusside test for acetone was positive and could be reversed by boiling of the urine. The serum acetone was qualitatively positive (Acetest tablet). The blood urea nitrogen was 27 mg., and the blood sugar 140 mg. per 100 cc., and the carbon dioxide 9 milliequiv., and the chloride 105 milliequiv. per liter. The prothrombin time was 10 per cent of normal; the blood bromide level was 0. A guaiac test of the stools was positive. The ferric chloride test for urine salicylate was strongly positive both before and after the urine was boiled. The pH of arterial blood was 7.15; the blood salicylate level was 90 mg. per 100 cc.

Since the patient's clinical appearance raised considerable doubt about spontaneous recovery, dialysis on a Kolff artificial kidney was begun 7½ hours after admission. After 1 hour respiration was noticeably more quiet; after 2 hours the patient was awake, attempting to speak and able to drink water, and by the 3d hour he was speaking rationally. The procedure was carried out for a total of 6 hours, with a mild hypotension (blood pressure of 80/60) as the only untoward effect. The fall in serum salicylate, the amounts removed in the bath and the dramatic changes in clinical state are shown in Figure 1. The recovery of 9.4 gm. of salicylate, with a net drop in the blood level of 57 mg. per 100 cc., is of particular interest.

On the following day the patient was awake and alert, complaining of weakness and nonproductive cough. The chest was clear on physical examination, but x-ray study revealed a small area of opacity in the left lower lobe, consistent with pneumonitis. The stools became guaiac negative. The blood pressure rose to 110/70. The prothrombin time gradually rose to normal by the 7th hospital day. No salicylate could be detected in the blood by the 3d hospital day. During the latter part of his stay the patient was questioned repeatedly about the amount of drug ingested. He steadfastly denied any suicide attempt but stated that he had obtained 7 bottles of aspirin about 8 weeks before admission and had begun to take them for headaches, at first 5 tablets a day, gradually increasing to 50 tablets a day. This gave him a pleasantly drowsy feeling along with blurred vision, diminished auditory acuity, sweating and occasional headache. He insisted that on the day before admission he had taken no more than the usual amount but had combined it with coca-cola, which, he claimed, had synergised the effect of the tablets. He had felt faint toward the evening before admission and then remembered no more until he awakened during the dialysis. The last few days of his hospital course were uneventful, and, after further psychiatric consultation, he was discharged on September 14. His account of the amount of aspirin ingested was considered unreliable.

Table 1. *Data in 2 Cases of Salicylate Poisoning.*

Case No.	Interval Between Ingestion and Admission hr.	Reason for Ingestion	Estimated Dose gm.	Treatment before Admission	Respirations		Clinical State	Chvostek & Trousseau Signs
					rate per min.	character		
1	19	Suicide	210 (in 8 wk.)	None	22	Deep & regular	Coma	Negative
2	30	Suicide	45 (1 dose)	Gastric lavage; fluids intravenously; sodium bicarbonate.	36	Deep & irregular	Patient awake & agitated	Negative

Case 2. A 19-year-old woman was admitted to Georgetown University Hospital on September 17, 1954, for treatment of aspirin poisoning. A history was obtained from the family of a suicide attempt with aspirin 1 year previously that had not required hospitalization. Subsequently, she had been under psychiatric care and successfully working as a dental x-ray technician for the past several months. At 4:00 p.m. on September 16, for unknown reasons, she claimed to have dissolved "1 bottle" (83 gm.) of aspirin in a glass of water and to have drunk about "half." The unreliability of her estimate of dose is emphasized by the poor solubility of aspirin in water. She was seen at another hospital 4 hours later, and a gastric lavage was performed. She was then discharged to the care of her parents, who were instructed in the signs of salicylism. Later that evening she began to complain of difficulty in hearing and was returned to the same hospital at 10:00 a.m. on September 17, awake, hyperpneic, restless and partially deaf. The carbon dioxide combining power was 24 milli-

equiv. per liter, and the prothrombin time was 50 per cent of normal. She was treated with vitamin K, sodium bicarbonate by mouth and fluids intravenously. Because of lack of improvement she was transferred to Georgetown University Hospital, where, on admission, she was drowsy but oriented. Speech was slurred, and she complained of a "roaring" sound in her ears. Physical examination revealed flushed facies, a hot, dry skin and deep, irregular respirations at 36 per minute. The blood pressure was 110/50; the pulse was 100, and the temperature 99.8°F. by rectum. Neurologic examination was unremarkable. The Chvostek and Trousseau signs were absent. Initial laboratory work showed a hematocrit of 41 per cent, a white-cell count of 16,950, a carbon dioxide of 31.5 milliequiv. per liter and a blood sugar of 165 mg. per 100 cc. The urine was clear yellow, negative for albumin and positive for sugar, acetone and salicylate; the sediment contained 5 to 10 red cells and 5 to 10 white cells per high-power field. The serum salicylate level was 91 mg. per 100 cc. Because approximately 30 hours had elapsed since the ingestion of aspirin without loss of consciousness, and also because of the opportunity for close observation, conservative management was considered justified, and intravenous administration of fluids and sodium lactate was started. The course over the next 6 days was one of progressively severe mental disturbances, including visual hallucinations and maniacal behavior, which reached their peak on the 4th day. She abruptly reverted to normal behavior on the 5th day and was discharged, asymptomatic, 1 day later to the care of her family and psychiatrist.

Serum salicylate had slowly declined and had disappeared by the 6th day. The recovery from the urine totaled 8.4 gm.

The significant admission data on the 2 patients and a comparison of the rates of fall in serum salicylate, together with the amounts recovered, are shown in Table 1 and Figure 2.

Discussion

Both patients exemplified in varying degrees the diagnostic features of salicylism, including hyperpnea, fever, hypoprothrombinemia, eighth-nerve and central-nervous-system signs, skin rash, positive ferric chloride test and decreased carbon dioxide combining power of blood. This reduction of carbon dioxide is due to respiratory alkalosis in the early stages and metabolic acodosis in the later stages of salicylism.[6]

The dramatic course of events in Case 1 left no doubts in the minds of all who saw the patient that dialysis had saved his life. Acknowledging the subjective basis for this impression, we searched the literature on adult salicylate poisoning in an attempt to correlate dose with fatal outcome. A representative sample[20-22] makes it clear that the variation is too great for one to predict survival or death on the basis of ingested dose, within the widest range. This is true from 2 gm. to 105 gm. However, the effect of the shortened morbidity and the rapid reversal of coma in decreasing the possibility of brain and pulmonary complications seems beyond question. A comparison of salicylate recovery from the 2 patients calculated as grams per hour (and allowing Case 2 a 30 per cent metabolic loss) shows that the artificial kidney removed salicylate about twenty times faster than normal urinary excretion. Doolan et al.,[17] in acute experiments with smaller doses, demonstrated an advantage for the artificial kidney of five to seven times the rate of excretion by normal kidneys.

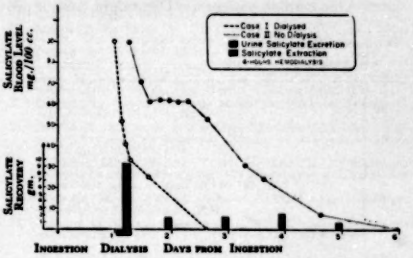

Figure 2. *Efficiency of Hemodialysis in Salicylism (Cases 1 and 2).*

It is clear from Table 1 that the clinical state of the patient cannot be predicted from the height of the serum salicylate. Factors such as the time-dose relation, treatment before admission and the underlying state of the patient — nutritional, psychic and otherwise — must all be involved. To have 1 patient awake and the other deeply comatose at similar blood levels raises questions concerning spinal-fluid levels, tissue levels and selective concentrations in brain or other organs that cannot be answered here.

The initial depression of prothrombin times and their return to normal are shown in Figure 3. It is interesting that Case 1 was still hypoprothrombinemic while his serum salicylate level was 0. Conversely, Case 2 had a normal prothrombin concentration before her serum salicylate had fallen to 0. The prothrombin-reducing effects of salicylate have been well documented in man[7] as well as the successful in-

Table 1 *(Concluded).*

Case No.	Blood Salicylate Level	Carbon Dioxide Combining Power	Prothrombin Time	Arterial pH	Serum Acetone	Urinary pH	Urinary Acetone	Urinary Ferric Chloride
	mg./100 cc.	*milliequiv./liter*	%					
1	91 (7 hr. after admission)	9	11 (43 sec.)	7.1	Positive	5.5	Positive	Positive
2	90 (on admission)	24	48 (20 sec.)	—	Negative	6.0	Positive	Positive

hibition of this action by vitamin K.[23] It is pertinent in this connection to recall that Dicumarol may be degraded in vitro to salicylic acid.[24] In experiments done in this laboratory doses of 200 to 300 mg. of Dicumarol failed to reveal detectable salicylate in plasma of healthy adults when tested twenty hours later. One cardiac patient, on Dicumarol, with a pro-

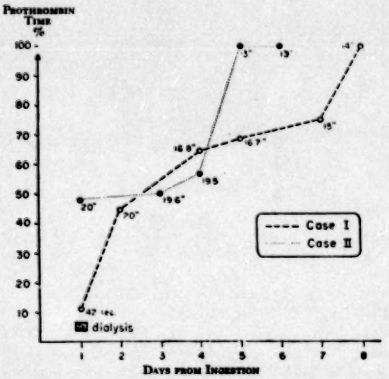

Figure 3. *Recovery of Prothrombin Time (Cases 1 and 2).*

thrombin time below 50 per cent, showed similar negative results. The small doses involved may well account for this. In addition to its hypoprothrombinemic effect salicylate has been cited as injurious to capillary walls and as a depressant of plasma fibrinogen.[1] In any event the bleeding tendency so induced only occasionally becomes a major clinical problem.[25]

The guaiac-positive stool in Case 1, with a history of suspected peptic ulcer, may be explained by the low prothrombin time. However, mention should be made of Hurst's[11] demonstration of gastric ulceration after salicylate ingestion. Although subsequent authors[26] failed to confirm the original report, recent unpublished observations[12] have clearly demonstrated gastric erosion in salicylate poisoning seen both with the gastroscope and on section of biopsy material. The process seems to be a necrosis of the neck cells in the foveola, with sloughing and superficial ulceration.

Certain speculations on salicylate distribution in the body are suggested by the data. Case 1 lost 9.4 gm. of salicylate, with a drop in blood level of 57 mg. per 100 cc.; this represents a volume of distribution of 16 liters. Similar calculations for Case 2 derive a volume of distribution (salicylate space) of 9.2 liters. In each case the "salicylate space" represented 18 to 21 per cent of total body weight — a figure compatible with extracellular fluids. These crude calculations neglect metabolic losses (25 to 50 per cent)[18] and tissue feedback and in no sense constitute definitive evidence on the anatomic distribution of salicylate.

To evaluate plasma-protein binding under conditions obtained with the Kolff artificial kidney, solutions of salicylic acid in plasma and saline were dialyzed as described under "Materials and Methods." The curves (Fig. 4) demonstrate that binding, to whatever extent it occurs, does not adversely affect the dialysis of salicylate.

The selection of patients with salicylism for dialysis must necessarily be tentative at present. From the standpoint of preventing or minimizing brain damage, pneumonia and atelectasis, coma is an emergency indication. Patients exhibiting central-nervous-system signs, with or without coma will probably benefit from the procedure. For lesser degrees of salicylism further experience is needed before recommendations can properly be made. Patients with depressed prothrombin times should receive vitamin K_1 oxide, and all patients, dialyzed or not, require meticulous attention to their fluid needs and acid-base disturbances as outlined in other papers.[1,6]

Summary

Two cases of salicylate poisoning are presented, 1 of which was successfully treated by hemodialysis. The patients are compared for blood levels, salicylate recoveries and clinical course. The value of the artificial kidney in quickly removing salicylates from the body is emphasized. In addition certain data concerning hypoprothrombinemia, salicylate distribution and plasma-protein binding are presented and discussed.

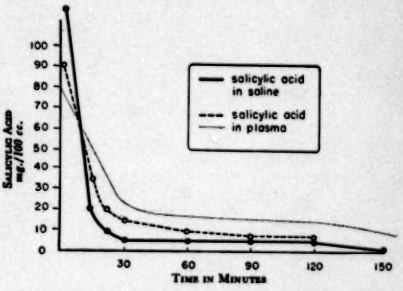

Figure 4. *In Vitro Dialysis of Salicylate.*

Since this paper was prepared for publication 2 more severe cases of salicylism have been seen at Georgetown Hospital. F.C. ingested 132 gm. of aspirin and died on admission nine hours after the ingestion. The blood salicylate level was 103 mg. per 100 cc. M.L. ingested 166 gm. of aspirin and was admitted sixteen hours later, with a blood level of 115 mg. per 100 cc. This was reduced to 29 mg. by a seven-hour dialysis, and the patient awakened and had a complete recovery of reflexes and faculties. However, multiple coagulation defects, with gastrointestinal hemorrhage, developed; she received 10 liters of blood and died five days later with generalized purpura and anuria. These experiences emphasize the fact that salicylism should be regarded as an acute medical emergency.

References

1. Winters, R. W. Salicylate intoxication in infants and children. *Gen. Practitioner* 10:67-72, 1954.
2. Krasnoff, S. O., and Bernstein, M. Acetylsalicylic acid poisoning. *J.A.M.A.* 138:712-714, 1947.
3. Goodman, L. S., and Gilman, A. *The Pharmacological Basis of Therapeutics: A textbook of pharmacology, toxicology and therapeutics for physicians and medical students.* 1583 pp. New York: Macmillan, 1941.
4. Dysart, B. R. Death following ingestion of 5 grains of acetylsalicylate acid. *J.A.M.A.* 101:446, 1933.
5. Graham, J. D. P., and Parker, W. A. Toxic manifestations of sodium salicylate therapy. *Quart. J. Med.* 17:153-163, 1948.
6. Singer, R. B. Acid-base disturbances in salicylate intoxication. *Medicine* 33:1-13, 1954.
7. Shapiro, S., Redish, M. H., and Campbell, H. A. Studies on prothrombin. IV. Preliminary observations on effect of salicylate in man. *Proc. Soc. Exper. Biol. & Med.* 53:251-254, 1943.
8. Forster, F. Personal communication.
9. Ryder, H. W., Shaver, M., and Ferris, E. Salicylism accompanied by respiratory alkalosis and spinal encephalopathy: report of fatal case. *New Engl. J. Med.* 238:617-621, 1948.
10. Ashworth, C. T., and McKenzie, J. F. Hemorrhagic complications with death probably from salicylate therapy: report of 2 cases. *J.A.M.A.* 126:806-810, 1944.
11. Hunter, A., and Linstead, G. A. M. Aspirin as cause of haematemesis: clinical and gastroscopic study. *Guy's Hosp. Rep.* 89:173-176, 1939.
12. Palmer, E. Personal communication.
13. Becke, B. E., Udenfriend, S., and Coburn, A. F. Determination of salicylic acid in plasma. *J. Pharmacol. & Exper. Therap.* 80: 114-117, 1944.
14. Keller, W. J., Jr. Rapid method for determination of salicylates in serum or plasma. *Am. J. Clin. Path.* 17:415-417, 1947.
15. Lester, D., Lolli, G., and Greenberg, L. A. Fate of acetylsalicylic acid. *J. Pharmacol. & Exper. Therap.* 87:329-342, 1946.
16. Abel, J. J., Rowntree, L. G., and Turner, B. B. On removal of diffusable substances from circulating blood of living animals by dialysis. *J. Pharmacol. & Exper. Therap.* 5:275-316, 1913.
17. Doolan, P. D., Walsh, W. P., Kyle, L. H., and Wishinsky, H. Acetylsalicylic acid intoxication: proposed method of treatment. *J.A.M.A.* 146:105, 1951.
18. Merrill, J. P., et al. Use of artificial kidney. I. Technique. *J. Clin. Investigation* 29:412-424, 1950.
19. Merrill, J. P., Smith, S. III, Callahan, E. J., III, and Thorn, G. W. Use of artificial kidney. II. Clinical experience. *J. Clin. Investigation* 29:425-438, 1950.
20. Levenson, I. Aspirin poisoning. *Brit. M. J.* 42:628-630, 1949.
21. Gross, M., and Greenberg, L. A. *The Salicylates: A critical bibliographic review.* 380 pp. New Haven: Hillhouse Press, 1948.
22. Cournot, L. Les tentatives de suicide par l'aspirine. *Semaine d. hôp. de Paris* 30:111-114, 1950.
23. Shapiro, S. Studies on prothrombin. VI. Effect of synthetic vitamin K on prothrombinopenia induced by salicylate in man. *J.A.M.A.* 125:546-548, 1944.
24. Stahmann, M. A., Huebner, C. F., and Link, K. P. Studies on hemorrhagic sweet clover disease. V. Identification and synthesis of hemorrhagic agent. *J. Biol. Chem.* 138:513-527, 1941.
25. Wintrobe, M. W. *Clinical Hematology.* Third edition. 1048 pp. Philadelphia: Lea & Febiger, 1951.
26. Caravati, C. M., and Cosgrove, E. F. Salicylate toxicity: probable mechanism of its action. *Ann. Int. Med.* 24:638-642, 1946.

PHARMACOLOGIC AND ANTIARRHYTHMIC ACTIONS OF AMBONESTYL (2-DIETHYLAMINOETHYL-ISONICOTINAMIDE) IN MAN*

Preliminary Report

BYRON B. CLARK, PH.D.,† AND BENJAMIN ETSTEN, M.D.‡

BOSTON

EXPERIMENTAL studies[1-3] suggested that certain chemical structures might be capable of suppressing ventricular arrhythmia without possessing some of the actions previously associated with antiarrhythmic drugs such as depression of cardiac conduction, elevation of ventricular electrical threshold, hypotension and local anesthetic activity. Ambonestyl (2-diethylaminoethyl-isonicotinamide, MC 4112) was found to be a compound with just such specificity. The chemical structure of Ambonestyl and its relation to procaine amide are shown below:

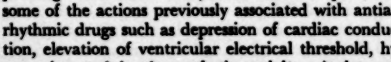

AMBONESTYL (MC 4112) PROCAINE AMIDE

Extensive laboratory investigation in animals[4] has demonstrated that Ambonestyl is as effective as procaine amide in the unanesthetized dog in suppressing persistent ventricular tachycardia and multiple premature ventricular contractions resulting from coronary-artery ligation (two stage[5]). The pharmacologic characteristics of Ambonestyl in comparison with those of procaine amide and quinidine are briefly summarized in Table 1.

TABLE 1. *Comparative Pharmacologic Characteristics of Ambonestyl, Procaine Amide and Quinidine.*

PROPERTY	AMBONESTYL*	PROCAINE AMIDE*	QUINIDINE*
Ventricular antiarrhythmic activity	++++	++++	++++
Cardiac actions:			
Conduction	0	−	−
Threshold	0	+	+
Refractory period	+	+(±)	+
Contractility	0	±	−
"Vagolytic"	+	+++	++++
Hypotension	+	+++	++++
Ganglionic block	+	+++	++++
Local anesthesia	0	±	+

*0 no effect; + increase; ± slight effect; − decrease or depression.

The experimental studies thus indicate that in clinical use Ambonestyl should have a wider margin of safety than procaine amide and quinidine, both of which, although frequently effective in suppressing arrhythmias, may depress cardiac conduction to a sufficient extent to limit their use in certain patients, especially those with conduction disturbances such as intraventricular (bundle-branch) block.[6,7] The hypotensive action of procaine amide[8,9] and quinidine[10] is also a serious limitation in cases in which intravenous administration may be indicated.

*From the departments of Pharmacology and Anesthesiology, Tufts University School of Medicine and New England Center Hospital.

Aided by grants from the National Heart Institute (H-1533 and H-1711), National Institutes of Health, Public Health Service, and the Squibb Institute for Medical Research.

†Professor of pharmacology and chairman, Department of Pharmacology, Tufts University School of Medicine; consulting pharmacologist, New England Center Hospital.

‡Professor of anesthesia, Tufts University School of Medicine; chairman, Department of Anesthesiology, New England Center Hospital.

This report describes some aspects of the immediate pharmacologic effects of Ambonestyl in man under controlled conditions, and the effects on ventricular arrhythmias as observed in surgical patients before and during surgical anesthesia.

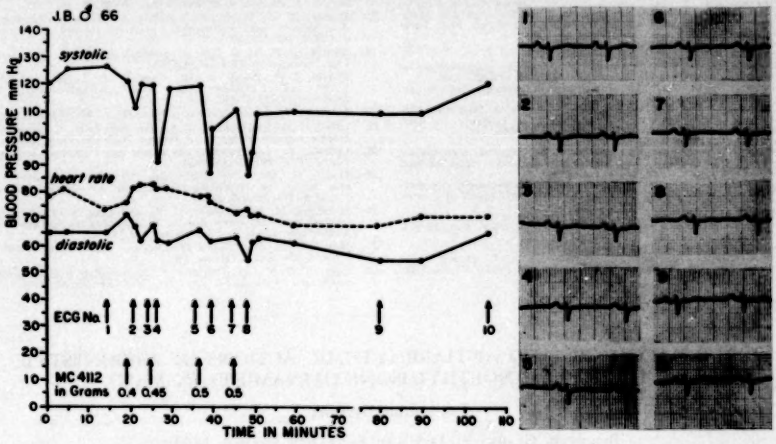

FIGURE 1. *Effect of Ambonestyl (MC 4112) on Blood Pressure and Electrocardiogram (Lead 2) in Case 3.*

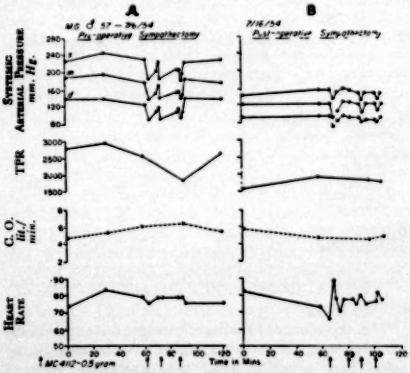

FIGURE 2. *Hemodynamic Effects of Ambonestyl (MC 4112) before and after Operative Sympathectomy in a Fifty-Seven-Year-Old Man with Essential Hypertension (Case 11A and 12B).*

METHODS AND MATERIALS

The initial pharmacologic observations were made on 8 unanesthetized patients with or without premedication. The action of the drug on arrhythmias was studied in 8 additional patients. The arrhythmias were ventricular in all but 1 case and either were present when the patient came to the operating room or developed during anesthesia or surgery or occurred postoperatively.

Each subject was prepared with an intravenous-drip set containing a three-way stopcock connected to an indwelling needle in the median basilic vein, and the drug was injected intravenously in a 5 per cent solution. All patients were in the supine position unless some other position was indicated. It was found that single doses of 0.5 gm. could be injected rapidly in five to ten seconds and repeated at ten-minute intervals until 1.5 to 2.5 gm. had been administered. This dosage schedule did not have any serious side effects and was used in the majority of the studies reported.

Electrocardiograms were taken at frequent intervals before and after administration of the drug and continuously during the period of administration by recording of the three standard limb leads simultaneously on a multichannel, direct-writing oscillograph. Blood pressure was measured frequently, usually by the indirect method, but on several occasions directly from the brachial artery by means of a Statham strain gauge (model P-23A) and recorded simultaneously with the electrocardiograms. Respiration was observed carefully although no quantitative measurements were made. Subjective effects were either volunteered or elicited in the unanesthetized patients.

More complete hemodynamic studies were carried out in 3 unanesthetized but lightly sedated patients. Cardiac output was measured by the dye-dilution

technic of Hamilton et al.[11] and Etsten and Li.[12] Blood pressure was determined directly from the brachial artery and recorded continuously, along with the electrocardiogram, as described above. The total peripheral resistance was calculated in the usual way from the mean arterial pressure and cardiac output.

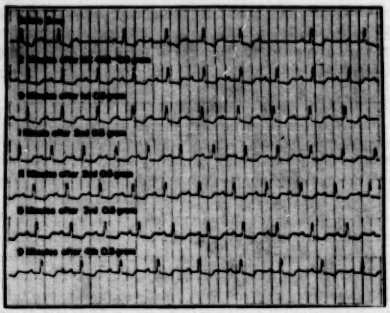

FIGURE 3. *Effects of Ambonestyl (MC 4112) on Conduction Disturbance Associated with Digitalization (Case 12). Note disappearance of dropped beats and shortening of the PR interval. Records were taken at the same time as the hemodynamic studies in Figure 2B.*

mg. each at ten-minute intervals (total 750 mg.) were a transient depression (lasting about five minutes) of the T wave in the electrocardiogram and a slight but very transient increase in heart rate. With this and larger single doses (500 mg.) a subjective sensation of warmth spreading over the body that lasted about thirty seconds after each injection was reported. No change in the color of the skin was noted, however.

Figure 1 shows the cardiovascular responses to Ambonestyl in a sixty-six-year-old unanesthetized man, scheduled for resection of the rectum, who received 0.4 to 0.5 gm. injected rapidly (in ten seconds) for a total of 1.85 gm. This subject was lightly sedated (6 mg. of morphine and 0.3 mg. of scopolamine) and presented no evidence of cardiovascular disease. There was a transient fall in systolic blood pressure after each dose, but much less change in diastolic pressure. The electrocardiogram revealed no significant change in the PR and QRS intervals indicating the absence of any effect on conduction. The T wave was depressed (but not the ST segment); there was rapid recovery of the T-wave change after the first dose, but with succeeding doses the T wave remained depressed and did not recover until forty-five minutes after the last injection. A brief sensation of warmth after each injection was the only subjective effect elicited. Slight respiratory stimulation lasting for only two or three breaths was noted.

TABLE 2. *Antiarrhythmia Studies with Ambonestyl in Man.*

Case No.	Age yr.	Sex	Condition	Anesthesia	Ambonestyl dosage gm.	Ambonestyl interval min.	Response
1	81	M	Atrial premature contractions	None	0.5	59*	None
5	68	M	Occasional premature ventricular contractions	Cyclopropane	1.0	8	Reduced frequency of contractions
6	72	M	Premature ventricular contractions (12-24 per min.)	Before & during cyclopropane	2.0	85	Complete suppression of contractions
7	30	F	Bigeminal rhythm; mitral commissurotomy.	Pentothal Sodium; curare; nitrous oxide.	2.5	135	Suppression of bigeminal rhythm
9	49	M	Premature ventricular contractions (18-24 per min.)	None (after operation)	1.5	135	Complete suppression of contractions
14	47	F	Bigeminal rhythm	Cyclopropane	1.5	6	Complete suppression of contractions
16	57	F	Bigeminal rhythm; cardiac surgery; digitalis.	Pentothal Sodium; nitrous oxide.	3.5	60	Complete suppression of contractions
12	57	M	Partial atrioventricular block, with dropped beats; digitalis.	None	1.5	30	Cessation of dropped beats & shortening of PR interval

*In this patient five 100 mg. doses given over 59 minutes; in remaining cases single doses of 0.5 gm. injected rapidly and repeated for total dose stated within interval indicated.

RESULTS

Pharmacology in Human Subjects

The initial observations in unanesthetized and lightly sedated subjects with no apparent cardiac disease revealed no detectable objective or subjective effects when Ambonestyl was injected rapidly (in ten seconds) in single doses of 100 mg. and when this dose was repeated at ten-minute intervals to a total dose of 500 mg.

The only effects noted after three injections of 250

More complete hemodynamic observations were made in 3 additional unanesthetized but sedated (with morphine and scopolamine) subjects with essential hypertension; Figure 2 shows the typical responses both before (*A*) and after sympathectomy (*B*) in a fifty-seven-year-old man. The rapid injection of Ambonestyl was followed by a transient fall in both systolic and diastolic blood pressure (direct arterial measurement). However, no significant change in cardiac output was recorded. The changes in heart rate were also, in general, not significant, except in

Part B of Figure 2, where the small increase may be due to the suppression of dropped beats (see Figure 3 and comments below). Considering all observations, there may be a trend for the total peripheral resistance (TPR) to decrease, but this trend is not very great. The significant decrease in TPR noted in one of the observations shown in Figure 2*A* is the only instance, thus far, in which a determination coincided with the peak of fall in blood pressure. These

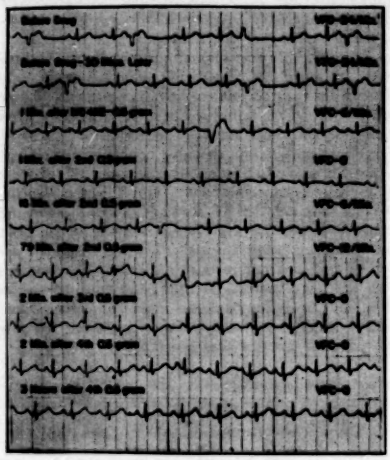

FIGURE 4. *Effects of Ambonestyl (MC 4112) on Premature Ventricular Contraction Occurring before and during Cyclopropane Anesthesia (Case 6 — Lead 2 throughout).*

Two 0.5-gm. doses before anesthesia suppressed the arrhythmia. Some time after anesthesia with cyclopropane the premature contractions reappeared and were again suppressed by two additional 0.5-gm. doses.

observations, along with an inspection of the pulse-pressure contours, suggest that the transient fall in blood pressure noted may be due to a brief peripheral vasodilatation. It is interesting that, after the last determination of cardiac output in this subject (Fig. 2*B*), a 20° upright tilt from the horizonal position did not result in any greater change in blood pressure than that seen with this test during the control period.

At the time of postoperative tests (Fig. 2*B*) the subject had been digitalized and, as shown in Figure 3, exhibited partial atrioventricular block, with frequent dropped beats and progressive lengthening of the PR interval (Wenckebach phenomenon). After the first injection of Ambonestyl the dropped beats no longer occurred, and the PR interval was temporarily shortened. When additional drug was administered the PR interval shortened further and was maintained within essentially normal limits.

Further evidence for the absence of any depressant effect of Ambonestyl on cardiac conduction was obtained in 2 other patients with right intraventricular (bundle-branch) block. One patient was a sixty-eight-year-old man, and the other a sixty-year-old woman. Both patients received two 0.5-gm. doses of the drug by rapid injections ten minutes apart. Careful measurement failed to show any increase in the QRS intervals or any other electrocardiographic changes except the depression of the amplitude of the T wave.

Antiarrhythmia Activity

The arrhythmia-suppressive activity of Ambonestyl was studied in 8 patients; the results are briefly summarized in Table 2 and illustrated in Figures 4-6.

A dosage-time-course response to Ambonestyl was observed postoperatively in an unanesthetized forty-nine-year-old male patient who exhibited frequent premature ventricular contractions. The arrhythmia was present before anesthesia but disappeared under moderately deep cyclopropane anesthesia. However, after colostomy and recovery from anesthesia, the premature ventricular contractions recurred at the same frequency as before. Ambonestyl was administered in three 0.5-gm. doses. The premature ventricular contractions were suppressed completely for twenty-five minutes after the first dose and for about fifteen minutes after the second. Then, after the third 0.5-gm. dose of the drug, the arrhythmia did not appear again during the period of observation.

The action of Ambonestyl on premature ventricular contractions occurring both before and during cyclopropane anesthesia is shown in Figure 4. This seventy-two-year-old man had persistent and frequent premature ventricular contractions before anesthesia. Ambonestyl, in two 0.5-gm. doses administered about five minutes apart, completely suppressed the arrhythmia for some time. During this interval anesthesia was induced with cyclopropane, and the operation for total gastrectomy begun. Premature ventricular contractions reappeared and were again suppressed by two additional 0.5-gm. doses.

Premature ventricular contractions appeared during deep cyclopropane anesthesia in a forty-seven-year-old woman undergoing a cervical dilatation and curettage. The bigeminal rhythm was constant for about ten minutes before the drug was administered. The abnormal rhythm was temporarily suppressed by 1.0 gm. of the drug and completely suppressed by a total of 1.5 gm. for the remainder of the forty-minute period of observation.

The action of Ambonestyl was studied in 2 cases of cardiac surgery for the exploration of the mitral valve or commissurotomy. Figure 5 illustrates some of the findings in a case of mitral commissurotomy. A bigeminal rhythm began with the induction of anesthesia and persisted continuously, despite adequate oxygenation, for ten minutes (electrocardiograms No. 1 and 2) until Ambonestyl, 0.5 gm., was injected. This dose suppressed the bigeminal rhythm for only two minutes (tracing No. 3), but an additional 0.5 gm.

resulted in sinus rhythm for ten minutes (tracing No. 6). Then, when the pericardium was opened and stay sutures placed, the bigeminal rhythm returned (tracing No. 7). An additional 0.5 gm. (total of 1.5 gm.) converted this rhythm to supraventricular tachycardia, probably sinus (tracing No. 8), and then this became clearly sinus except during mechanical stimulation of the ventricle (tracing No. 9). The bigeminal rhythm recurred when stay sutures were placed in the atrium (record No. 15), which immediately reverted to the supraventricular rhythm (record No. 16). Then the atrium was sutured, and the pericardium and chest closed, all without any further occurrence of ventricular ectopic rhythm.

Another example in which Ambonestyl was used in cardiac surgery is illustrated in Figure 6. The patient, a fifty-seven-year-old woman, was scheduled for a mitral commissurotomy but on exploration was found to have a primary tumor arising from the interatrial septum with a pedicle that extended through the mitral valve and, by its ball-and-valve action, produced the clinical picture of mitral stenosis. Because of a previous episode of congestive heart failure the patient was also receiving digitalis. As shown in Figure 6, a bigeminal rhythm developed when the pericardium was opened, and was for the most part persistent although there were occasional short runs of regular sinus rhythm. The administration of Ambonestyl was initiated and six 0.5-gm. doses (total of 3.0 gm.) were given over approximately thirty-five minutes, with only intermittent periods of sinus rhythm. An additional 0.5 gm. completely suppressed the bigeminal rhythm. The only episode of recurrence of the bigeminal rhythm was for a one-minute period when the surgeon's finger was exploring the mitral valve and the left ventricular wall. During this exploration, the tumor was displaced from the valve. The atrium, pericardium and chest were closed without further abnormalities in rhythm.

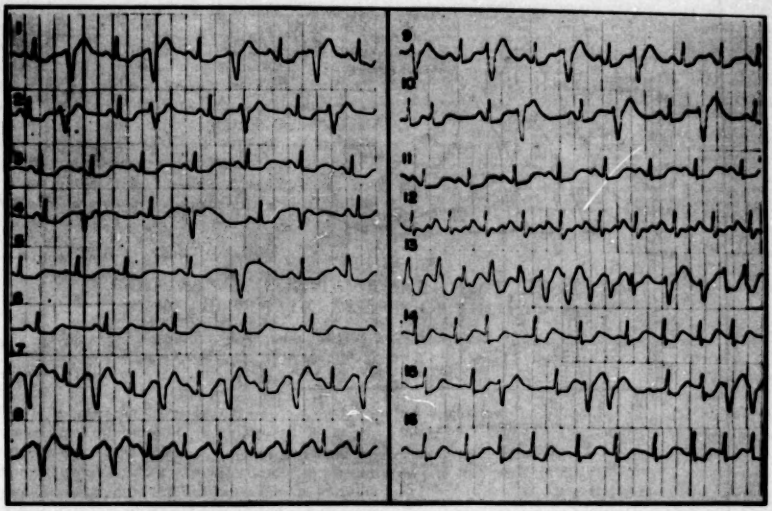

FIGURE 5. *Effect of Ambonestyl (MC 4112) on Ventricular Arrhythmias before and during Mitral Commissurotomy (Case 7).*

(tracing No. 10). Another 0.5-gm. dose of Ambonestyl (total of 2.0 gm.) restored sinus rhythm (tracing No. 11) despite a clamp on the atrial appendage and incision of the appendage. Between records No. 11 and 12 a supraventricular tachycardia of higher rate appeared coincident with biopsy of atrial tissue. Neostigmine, 0.5 mg., administered at this time, effectively slowed the rate. The mitral valve was then explored with the finger, and at this time a run of atrial flutter appeared (record No. 12), which subsided after the surgeon removed his finger from the atrium. Supraventricular tachycardia then remained the dominant rhythm. When the valve was actually fractured there was a short run of ventricular tachycardia (record No. 13) that subsided immediately after removal of the finger from the valve (record No. 14). To test whether more of the drug would protect against the effects of mechanical stimulation of the heart another 0.5-gm. dose was given (total of 2.5 gm.), and the mitral valve again dilated. This manipulation still produced a short run of ventricular ectopic activity

Discussion

The pharmacologic investigation of the actions of Ambonestyl in man has demonstrated that it has a relatively wide margin of safety. In no case was there evidence of depression of cardiac conduction; this was true for patients with normal conduction as well as for those with intraventricular (bundle-branch) block. The apparent improvement in atrioventricular conduction noted in the digitalized patient may be explained on the basis of the weak depressant action of Ambonestyl on the cardiac vagus, along with the lack of any depressant action on atrioventricular conduction.

Persistent hypotension was not observed. A transient moderate fall in blood pressure was evident for only one to three minutes after the rapid administration of relatively large doses, and was of minor significance. Since no significant change in cardiac output was noted, this brief hypotension was probably due to a transient peripheral vasodilatation. Thus, both in man and in the dog,[4] the hypotensive action of Ambonestyl was significantly less than that reported for procaine amide,[8,9] and this may be explained by the fact that it has only one third of the ganglionic-blocking activity.[4] The sinus heart rate was, in general, not influenced to any appreciable extent.

Summary and Conclusions

Ambonestyl was effective, without exception, in suppressing premature ventricular contractions and bigeminal rhythms under the conditions of the clinical trials reported here. Although the number of patients treated is small each test was carefully controlled, and each patient for the most part served as his own control. In most cases a dose-time-effect relation was evident — that is, with smaller doses, the arrhythmia was only temporarily suppressed and tended to recur later, but after larger doses the arrhythmia remained suppressed for longer periods. In some patients a total dose of 2.5 to 3.0 gm. was required to obtain persistent suppression of the arrhythmia. Such doses were attained by intravenous administration of 0.5-gm. amounts at ten-minute intervals. Even when large amounts of the drug were necessary to suppress the ventricular arrhythmia undesirable side effects were not observed.

The effectiveness of Ambonestyl in atrial arrhythmias remains to be determined, since this study only included 1 patient with premature atrial contractions who did not respond to a small dose of the drug.

The 2 patients who received Ambonestyl during operation were regarded as Grade 4 cardiac surgical risks. It was believed that the drug was of definite

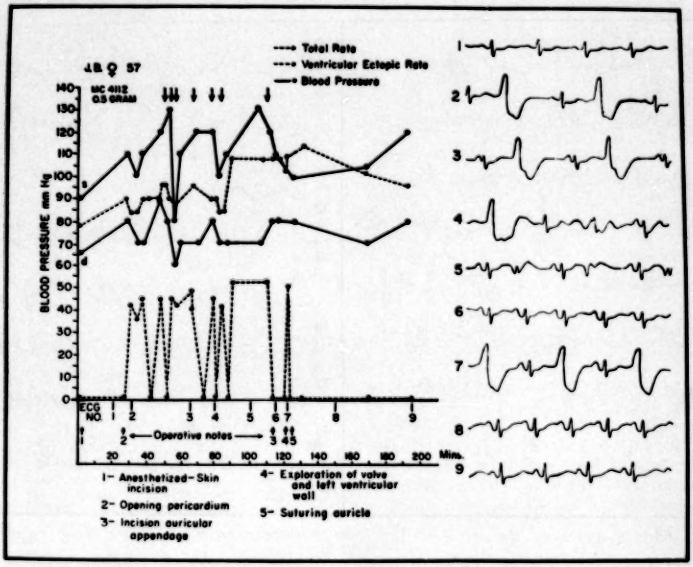

Figure 6. *Effect of Ambonestyl (MC 4112) on Bigeminal Rhythm Occurring during Cardiac Surgery (Case 16).*

clinical value in controlling the ventricular ectopic activity and in maintaining more normal cardiac function during the operative procedure.

These preliminary results indicate that Ambonestyl may have some advantages over procaine amide and quinidine in the treatment of ventricular arrhythmias in some cases and that further clinical evaluation is desirable. So far, the principal advantages appear to be the absence of depression of cardiac conduction and the lack of serious hypotension on intravenous administration. The fact that Ambonestyl can be administered rapidly and in large amounts permits the attainment of an effective dosage quickly when the acute treatment of an arrhythmia is necessary. Furthermore, this wide margin of safety seems to justify trial with more prolonged administration in recurrent and established arrhythmias. The data suggest that Ambonestyl might be particularly useful in treating arrhythmias in patients with conduction disturbances, in controlling arrhythmias during anesthesia and in patients undergoing cardiac surgery.

References

1. Newman, P. J., and Clark, B. B. Cardiovascular effect of procaine amide. *Federation Proc.* **10**:326, 1951.
2. Stern, H., Yelnosky, J., and Clark, B. B. Action of procaine amide on ventricular tachycardia produced by coronary artery ligation. *Federation Proc.* **11**:393, 1952.
3. Lanzoni, V. Investigation of actions of antiarrhythmia agents with particular reference to procaine amide. Thesis, Tufts College, 1953.
4. Lanzoni, V., and Clark, B. B. Antiarrhythmic action of Ambonestyl (2-diethylaminoethyl-isonicotinamide). *Circulation Research* (in press).
5. Harris, A. S. Delayed development of ventricular ectopic rhythms following experimental coronary occlusion. *Circulation* **1**:1318-1328, 1950.
6. Wedd, A. M., Blair, H. A., and Warner, R. S. Action of procaine amide on heart. *Am. Heart J.* **42**:399-405, 1951.
7. Sokolow, M. Present status of therapy of cardiac arrhythmias with quinidine. *Am. Heart J.* **42**:771-797, 1951.
8. McClendon, R. L., Hansen, W. R., and Kinsman, J. M. Hemodynamic changes following procaine amide administered intravenously. *Am. J. M. Sc.* **222**:375-381, 1951.
9. Schoolman, H., Pascale, L. R., Bernstein, L. M., and Littman, A. Arterenol as adjunct to treatment of paroxysmal tachycardia. *Am. Heart J.* **46**:146-149, 1953.
10. Ferrer, M. I., et al. Some effects of quinidine sulphate on heart and circulation in man. *Am. Heart J.* **39**:816-837, 1948.
11. Hamilton, W. F., et al. Comparison of Fick and dye injection methods of measuring cardiac output in man. *Am. J. Physiol.* **153**: 309-321, 1948.
12. Etsten, B. E., and Li, T. H. Determination of cardiac output by dye dilution method: modifications, comparison with Fick method, and application during anesthesia. *Anesthesiology* **15**:217-230, 1954.

IMPORTANCE OF POTASSIUM IN HEAT EXHAUSTION IN FIBROCYSTIC DISEASE OF THE PANCREAS*

SEYMOUR J. HARRIS, M.D.,† AND RICHARD L. LESTER, M.D.‡

LOS ANGELES, CALIFORNIA

SINCE Kessler and Andersen[1] first described the unusual susceptibility of the child with fibrocystic disease to heat exhaustion, a number of investigations have been carried out in an attempt to explain the factors responsible for this phenomenon. Studies have been directed primarily toward the composition of sweat in patients with this disease, for profuse diaphoresis is the chief manifestation of heat exhaustion.[2] Subsequent reports suggest that a basic defect in the sweat glands of fibrocystic patients is responsible for an increased excretion of sodium, chloride and potassium.[3,4] It is our purpose to emphasize the importance of the therapeutic administration of potassium in the treatment of heat exhaustion in fibrocystic disease and to point out the possible use of potassium in its prophylaxis.

Two cases of heat exhaustion in fibrocystic disease that occurred during a "heat wave" in July, 1954, in the otherwise temperate climate of Southern California, are presented below. Local climatologic data indicate that July, 1954, was the second warmest July on the records of the Los Angeles weather bureau. There were fourteen days in which the temperature was 90°F. or above. The average maximal temperature for the month was 87.1°F., which is approximately 4° above the normal, average, maximal temperature for July. There was, however, no significant variation in relative humidity during that month.[5]

*From the Children's Hospital.
†Formerly, senior resident in pediatrics, Children's Hospital.
‡Formerly, junior resident in pediatrics, Children's Hospital.

Case Reports

CASE 1. B. L., a 2-year-old boy, was admitted to the hospital on July 19, 1954, with a 4-day history of anorexia, vomiting, lethargy and profuse sweating. A sister had died at four years of age of fibrocystic disease of the pancreas. At 3 months of age the patient had intermittent diarrhea with large frothy, foul-smelling stools, frequent upper respiratory infections and a chronic cough. The weight gain was poor; a stool specimen examined by a private physician failed to show any tryptic activity. A tentative diagnosis of fibrocystic disease was made, and a regimen of protein-banana powder milk (Probana), pancreatic enzyme supplement and continuous antibiotics by mouth was initiated. At 16 months of age antibiotics were discontinued. The diarrhea became less intense, and he gained weight. In the month before admission the respiratory symptoms had subsided. His mother had always voluntarily maintained him on a modified low-salt diet, with no added dietary salt to his food.

Physical examination showed a well developed and fairly well nourished, acutely ill, moderately dehydrated and extremely drowsy boy. He was irritable when disturbed. The temperature was 98.6°F., the pulse 100, and the blood pressure 80/45. A slight amount of perspiration was present. The respirations were slow and shallow, and no abnormal lung findings were detected. There was generalized muscular weakness, with hypoactive deep tendon reflexes.

The history and clinical picture suggested fibrocystic disease with heat exhaustion as described by Kessler and Andersen.[1] The appearance was one of alkalosis and hypopotassemia. This clinical impression was confirmed by a carbon dioxide of 33 milliequiv., chloride of 88 milliequiv.,

sodium of 128 milliequiv. and potassium of 2.8 milliequiv. per liter. Therapy was designed to correct the fluid and electrolyte deficit. The amounts of fluid and electrolytes are recorded in Table 1. In retrospect, it was apparent that an inadequate amount of potassium was given during the 1st 3 days. Hydration was improved on the 2d day although the lethargy remained unchanged, and serum chemical determinations revealed persistence of hypochloremic alkalosis. It was necessary to continue parenteral administration of fluids and electrolytes for 4 days before the serum electrolytes returned to normal. Clinical improvement was slow; oral nourishment was refused until the 3d day. At that time the patient began to appear more alert and to show some interest in his surroundings. Not until the 5th day did he

amount calculated to furnish a total of 2 milliequiv. per kilogram of body weight during the first 24 hours. Four and a half hours after admission a generalized convulsion occurred and was followed by coma. Respirations slowed and gradually became more labored. Intravenous administration of calcium, coramine and epinephrine and manual artificial respiration were without benefit, and she died 5 hours after admission. Examination of a specimen of blood obtained 2 hours after admission showed a carbon dioxide of 29 milliequiv., a chloride of 58 milliequiv. and a potassium of 3.3 milliequiv. per liter. The red-cell count was 4,200,000, with a hemoglobin of 15.2 gm. per 100 cc., and the white-cell count 28,000, with 72 per cent granulocytes.

At autopsy moderate cardiac hypertrophy, old fibrous

TABLE 1. *Daily Fluids and Electrolytes in Case 1.*

DATE	FLUIDS GIVEN			SODIUM CHLORIDE GIVEN	POTASSIUM GIVEN		pH	BLOOD CHEMICAL CONSTITUENTS				URINARY pH
	TOTAL	PARENTERAL ADMINISTRATION	DAILY ADMINISTRATION		TOTAL	DAILY ADMINISTRATION		CARBON DIOXIDE	CHLORIDE	SODIUM	POTASSIUM	
	cc.	*cc.*	*cc./kg.*	*gm.*	*milliequiv.*	*milliequiv./kg.*		*milliequiv./liter*	*milliequiv./liter*	*milliequiv./liter*	*milliequiv./liter*	
7/20	1850	1850	132	5.3	16	1.1	—	33	88	128	2.8	5
7/21	1200	1200	86	3.0	17	1.2	7.59	28	90	123	3.0	5.5
7/22	1040	660	75	4.1	11	0.8	—	26	87	—	—	6.5
7/23	1450	950	103	4.1	47	3.0	—	23	97	137	5.2	—

demonstrate normal alertness and responsiveness. Later, a diagnosis of fibrocystic disease was made when duodenal aspiration revealed an absence of tryptic activity.

CASE 2. C. M., a 6½-year-old girl, was first admitted to the hospital on August 1, 1954. A diagnosis of fibrocystic disease of the pancreas, confirmed by duodenal aspiration, had been made in March, 1953, while the patient, then 5 years old, was in the Tripler Army Hospital in Hawaii. Before she was 3 years of age she had a few mild "colds" and only an occasional, large, foamy stool. Subsequently, she had frequent upper respiratory infections, a chronic cough and some dyspnea. On the usual fibrocystic type of diet, pancreatic enzyme supplement and prophylactic antibiotics she gained weight and remained free of severe infections.

Three days before admission she became anorectic and somewhat listless. At this time she ceased taking salt tablets that had previously been prescribed by her private physician. In the belief that the exceedingly hot weather was affecting her adversely, the entire family motored that night to Yosemite National Park, a distance of 353 miles, in search of cooler weather. However, her symptoms became progressively worse, and on the day before admission, she was driven back to Los Angeles during the middle of the day in a temperature of approximately 100°F. During the trip she vomited several times. That night she was seen by her physician, who administered 1000 cc. of 1/6 molar sodium lactate by hypodermoclysis at the patient's home. The next morning she continued to vomit, appeared in shock and was immediately referred to the hospital.

On admission she was moribund, cyanotic and obviously in shock. The respirations were shallow and gasping. The temperature was 97.5°F.; the pulse was 140, rapid and thready and the blood pressure was unobtainable. She was malnourished and chronically ill. Sweating was not prominent. There were fine and medium moist rales throughout both lungs. Peripheral vascular collapse prevented venesection for blood chemical determinations. Intravenous infusion of hypotonic Ringer solution (0.6 per cent sodium chloride) was administered, and a few minutes later a 2d infusion was started with 250 cc. of blood plasma. During the first two hours she received intravenously approximately 1000 cc. of fluids containing 6 gm. of sodium chloride. She improved rapidly, with slow disappearance of the signs of shock. After some improvement in hydration and evidence of re-established renal function potassium chloride was cautiously added to the fluids for parenteral injection in an

pericarditis, purulent bronchitis and bronchopneumonia, nonspecific enterocolitis, pancreatic fibrosis and congenital hypoplasia of the right kidney were found. The brain and spinal cord were normal.

The family history is of considerable interest. A female sibling, aged 15 months, had died of "bronchopneumonia." A 5-year-old brother, who allegedly had fibrocystic disease, died 2 weeks before this patient's death at another hospital, presumably of heat exhaustion.

Case 1 represents a fairly typical example of heat exhaustion in fibrocystic disease. It seems likely that the patient's restricted salt intake increased his susceptibility to the deleterious effects of heat. The initial blood chemical determinations were not obtained until approximately six hours after admission, when some rehydration had already taken place. This may explain the unusually low serum potassium level of 2.8 milliequiv. per liter on the first day, in contrast to the normal or slightly elevated levels frequently present in dehydrated patients.[6] Despite vigorous fluid and salt therapy the hypochloremic alkalosis required four days for complete chemical correction. A delay in response in severe hypokalemic states has been observed by others and is thought to represent the period necessary for restoration of the intracellular potassium deficit.[7-9] Nevertheless, it should be noted from the figures in Table 1 that, during the first three days of therapy, potassium was given in relatively small amounts, averaging about 1 milliequiv. per kilogram of body weight per day whereas adequate, safe therapeutic amounts are usually considered to be 2 to 3 milliequiv. per kilogram per day.

In Case 2 severe fibrocystic disease and far-advanced pulmonary changes were present. In addition to salt restriction she had severe vomiting, as

well as the insults of extreme heat and a large bicarbonate load in the form of 1000 cc. of one-sixth molar sodium lactate. The combination of factors was ideal for the development of severe hypochloremic alkalosis. Some estimation of the severity of chloride deficit can be obtained from the very low plasma chloride level of 58 milliequiv. per liter after two hours of vigorous salt and fluid therapy. The cause of the sudden death in this child is not readily apparent from the post-mortem findings. Severe electrolyte imbalance could certainly have led to irreversible changes, especially in a child with a hypoplastic kidney and an inadequate renal reserve.

Discussion

To substantiate the importance of potassium in this syndrome it may be helpful to discuss some of the present concepts of potassium metabolism. Darrow and his co-workers[10,11] demonstrated a biologic equilibrium between three variables: serum bicarbonate, intracellular potassium and intracellular sodium. Accordingly, the serum bicarbonate varies directly with the intracellular sodium and inversely with the intracellular potassium. The relative importance of this relation, as compared with the better known renal regulations of the extracellular fluid compartment, has been difficult to ascertain. Though renal regulation must eventually determine extracellular composition, there are factors that cannot be explained by renal action alone.

In nephrectomized, potassium-deficient, alkalotic rats, Orloff, Kennedy and Berliner[12] were able to correct the hypochloremic alkalosis with the intravenous infusion of potassium salts alone. Thus, the correction of alkalosis must depend, at least partially, on an extrarenal mechanism. This appears to be related to a shift of hydrogen ions into and out of the intracellular compartment, under conditions of intracellular potassium loss or the restoration of intracellular potassium deficit.[13] By muscle analysis it has been shown that in potassium deficiency, a loss of three potassium ions from the intracellular compartment is associated with a gain of only two sodium ions. It has also been shown that the remaining replacement ion is not calcium or magnesium.[14] It must therefore be hydrogen ion, which is readily available from the extracellular fluid. It follows, then, that as potassium enters the cell in the correction of potassium deficiency, hydrogen ion is released to the extracellular fluid. This results in a lowering of the serum bicarbonate and may be summarized by the following equation:

$$H^+ + Cl^- + Na^+ + HCO_3 \rightleftharpoons Na^+ + Cl^- + H_2CO_3 \rightleftharpoons CO_2 + H_2O$$

Provided there is sufficient fixed chloride anion the reaction can go in either direction.

Cooke et al.[15] have pointed out, however, that the reaction described above will not account for the persistence of alkalosis in potassium deficiency unless there is an additional alteration of renal function. The exact mechanism of this is not well understood but is thought to be related to a failure of the cells of the renal tubules to exchange organic anion for filtered chloride anion. In the presence of adequate potassium, citrate metabolism within the renal tubules appears to be accelerated, citrate being exchanged for chloride anions in amounts necessary to produce reabsorption of sodium and chloride in a normal ratio. Potassium deficiency alters this ratio.

It is probable that potassium deficiency is responsible for alterations not only in the extracellular electrolyte composition but also in the extracellular fluid volume. Cooke et al.[15] were able to correct hypochloremic alkalosis in rats by the administration of potassium bicarbonate alone during a period when sodium and chloride were withheld from the diet. The apparent rise in the serum chloride can be explained only by a decrease in the extracellular fluid volume. Potassium deficiency is therefore associated with a hypotonic expansion of the extracellular fluid as well as a deficiency in extracellular hydrogen ion, with resultant hypochloremic alkalosis. This concept has been borne out by Cheek,[16] who showed that total body chloride of potassium-deficient children is not low (with adequate intake of sodium, chloride and water) even though the amount of serum chloride per unit is low.

In the presence of a normal potassium and adequate chloride intake Cooke and his associates[15] were unable to produce alkalosis in rats. In their experiments the minimal intake of potassium that prevented alkalosis when chloride was moderately plentiful did not prevent alkalosis when chloride was markedly restricted.

In hot weather, patients with fibrocystic disease lose three times as much chloride, twice as much sodium and about one and a half times as much potassium in their sweat as controls. This, in association with the characteristic vomiting of heat exhaustion, leads to dehydration and a deficit of both potassium and chloride, a condition ideal for the development of alkalosis. If one attempts to correct this with a solution of sodium chloride alone a biologic equilibrium will be established, as described above, with a hypotonic expansion of the extracellular fluid. The equilibrium of a low serum chloride and high bicarbonate will persist until adequate potassium is administered.

The evidence that potassium is of major importance in the production and correction of the hypochloremic alkalosis in such cases is substantial and convincing. We therefore advocate vigorous parenteral potassium therapy. This should be started immediately after partial correction of the associated

dehydration, with restoration of adequate renal blood flow. A note of caution is interjected here, since the introduction of large amounts of potassium into a severely anhydremic circulation, with greatly diminished renal function, may lead to a state of relative hyperkalemia. The use of potassium parenterally in the amounts of 2 or 3 milliequiv. per kilogram of body weight per day (or 0.15 to 0.23 gm. per kilogram) is usually considered safe for infants and small children.[10,11] The deficit of sodium and chloride must be corrected with the immediate use of adequate amounts of sodium chloride solution, preferably hypotonic, at the onset.

It is now generally the practice to administer salt tablets to fibrocystic patients during the summer months. Because of the importance of potassium in the mechanism of hypochloremic alkalosis the additional oral use of potassium in the prophylaxis of heat exhaustion in children with this disease seems advisable, especially in the presence of anorexia. The foods that are usually included in the fibrocystic diet contain a fairly large amount of potassium.[17] Whether this is adequate in periods of unusual heat stress is a problem that deserves further investigation. Nevertheless, in children with normally functioning kidneys, little harm can be expected from additional potassium by mouth, and the data presented above suggest that benefit may result from its use.

Summary

Two cases of heat exhaustion in patients with fibrocystic disease are reported. A review of some of the concepts of potassium metabolism, with particular emphasis on the role of potassium in hypochloremic alkalosis, is presented. The importance of adequate parenteral potassium in the therapy of heat exhaustion is stressed. It is suggested that the oral use of potassium in addition to salt may prove beneficial in the prophylaxis of heat exhaustion in fibrocystic patients.

We are indebted to Dr. Phillip E. Rothman for his suggestions in the preparation of this article.

References

1. Kenker, W. R., and Andersen, D. H. Heat prostration in fibrocystic disease of pancreas and other conditions. *Pediatrics* 8:648-656, 1951.
2. Friedfeld, L. Prophylaxis and treatment of heat-reaction states. *New Eng. J. Med.* 240:1043-1047, 1949.
3. Darling, R. C., di Sant'Agnese, P. A., Perera, G. A., and Andersen, D. H. Electrolyte abnormalities of sweat in fibrocystic disease of pancreas. *Am. J. M. Sc.* 225:67-70, 1953.
4. di Sant'Agnese, P. A., Darling, R. C., Perera, G. A., and Shea, E. Abnormal electrolyte composition of sweat in cystic fibrosis of pancreas. *Pediatrics* 12:549-563, 1953.
5. U. S. Department of Commerce. Weather Bureau. Local climatological data. 1954.
6. Darrow, D. C. Body fluid physiology: role of potassium in clinical disturbances of body water and electrolyte. *New Eng. J. Med.* 242:1014-1018, 1950.
7. Pickering, D. E., and Winters, R. W. Fluid and electrolyte management in children. *Pediat. Clin. North America* (November), 1954. Pp. 873-899.
8. Elkinton, J. R., and Tarail, R. Present status of potassium therapy. *Am. J. Med.* 9:200-207, 1950.
9. Howard, J. E., and Carey, R. A. Use of potassium in therapy. *J. Clin. Endocrinol.* 9:691-713, 1949.
10. Darrow, D. C. Changes in muscle composition in alkalosis. *J. Clin. Investigation* 25:324-330, 1946.
11. Darrow, D. C., Schwartz, R., Iannucci, J. F., and Coville, F. Relation of serum bicarbonate concentration to muscle composition. *J. Clin. Investigation* 27:198-208, 1948.
12. Orloff, J., Kennedy, T. L., Jr., and Berliner, R. W. Effect of potassium in nephrectomized rats with hypokalemic alkalosis. *J. Clin. Investigation* 32:538-542, 1953.
13. Cooke, R. E., Segar, W. E., Cheek, D. B., Coville, F. E., and Darrow, D. C. Extrarenal correction of alkalosis associated with potassium deficiency. *J. Clin. Investigation* 31:798-805, 1952.
14. Cotlove, E., Holliday, M. A., Schwartz, R., and Wallace, W. M. Effects of electrolyte depletion and acid-base disturbance on muscle cations. *Am. J. Physiol.* 167:665-675, 1951.
15. Cooke, R. E., et al. Role of potassium in prevention of alkalosis. *Am. J. Med.* 17:180-195, 1954.
16. Cheek, D. B. Total body chloride of children in potassium deficiency and under circumstances of poor nutrition. *Pediatrics* 14:193-200, 1954.
17. California Dietetic Association. Compilation of diets. 143, 1942.

REVIEW OF FIFTEEN YEARS' EXPERIENCE WITH GASTRECTOMY IN A COMMUNITY HOSPITAL

II. Cancer

Paul R. Hinchey, M.D.*

Salem, Massachusetts

From 1939 to 1953 only 46 gastrectomies were performed at the Salem Hospital for carcinoma of the stomach. This is 39 per cent of all patients in whom this discharge diagnosis was made. Unoperated patients in whom no biopsy was obtained may be a minor source of diagnostic error. It is gratifying to observe the steady increase in the number of resectable cases as reported in large series throughout the country. Welch and Allen[45] reported a resectability of 50 per cent at Massachusetts General Hospital from 1937 through 1946. Pack[46] recently cited a rate of 65 per cent, and, even more recently, Kremen[47] one of 85 per cent. Since the experience at Salem Hospital was not sufficient to permit conclusions, opinions were sought from a number of recognized authorities, and in addition pertinent literature for the past eight years was reviewed.

The small, fairly constant number of patients on whom gastrectomy is performed each year for carcinoma in this hospital is in contrast to the steady increase in the number of gastrectomies for duodenal or gastric ulcers. Welch[48] recently stated that the incidence of gastric carcinoma was diminishing in his experience. Gastrectomy was performed with the hope of cure in 29 cases. In the remaining 17 the surgeon estimated that he was performing a palliative operation because of either the gross extent of disease

*Surgeon, Salem Hospital.

in the stomach or the presence of obvious metastases in organs such as the liver and pancreas. Only 2 total gastrectomies were done. The carcinoma was located in the distal third of the stomach in 23 cases, in the middle third in 10 and the proximal third in only 1. The pathologist described the tumor as extensive within the stomach in 11 cases, in most of which inadequate margins of stomach wall on each side of the gross carcinoma had been obtained. It seems reasonable to conclude that total gastrectomy was indicated in many of these 11 patients with extensive tumors, if not in all. A thoracoabdominal or transthoracic gastrectomy was performed in 6 cases. Five of 46 patients with resections have survived for over five years without evidence of recurrence. One of these died from a cerebral hemorrhage seven years after operation; autopsy demonstrated no residual carcinoma. Four additional patients are surviving, in apparent good health, three and a half to four years after operation.

Thus, the five-year cure rate is 4 per cent for all hospitalized patients. The operative mortality was 31 per cent for the entire series but has naturally been reduced steadily (8 per cent in the small number of operations done since 1950). Frequently, a rate of 10 per cent or less is cited for operations during a more recent five-year period. Abrahamson and Hinton[49] reported an operative mortality of 62 per cent in a series of operations between 1939 and 1945.

The anatomic location of the stomach does not permit such wide excision of adjacent structures as may be possible in carcinoma of the oral or pelvic cavity. Gastric carcinoma tends to metastasize early and widely by direct extension, by lymphatic and blood-vessel invasion, and by gravity seeding of the peritoneum. Meissner[50] describes blood-vessel invasion in 56 per cent of surgically resected specimens. Allison and Borrie[51] outlined the potential zone of available lymphatic spread as extending from the umbilicus to above the collar bone. Lymph-node metastases have already occurred by the time gastrectomy is performed in 75 per cent[52] to 85 per cent[53] of the cases. Valid comparison may be made between carcinoma of the tongue and cervix and pulmonary or gastric carcinoma. Many patients die of uncontrolled cancers of the tongue or cervix still confined above the clavicle or below the pelvic brim at the time of death. However, in only about 10 per cent of uncontrolled gastric carcinomas is the tumor still confined to the stomach or the immediate, resectable environs at the time of autopsy. In many organs radiation therapy plays an auxiliary or principal part, but *no form of treatment except surgery* is of value in gastric carcinoma. Therefore, the surgeon should familiarize himself with newer accomplishments in the surgery of gastric carcinoma such as total gastrectomy, thoracoabdominal gastrectomy and compound gastrectomy, adapting these more recent extensions of the surgical attack to his ability and facilities.

The following program represents personal conclusions concerning the management of gastric carcinoma *at the Salem Hospital:*

The precursors of gastric carcinoma must be observed more closely and operated on more often. All gastric polyps should be operated on immediately. Routine gastric aspirations are essential both for the determination of acidity and for cytologic examination. There is place for an occasional exploratory laparotomy and partial distal gastrectomy on some patients with gastric anacidity and mucosal irregularity in whom a final preoperative diagnosis cannot be made by x-ray survey. Gastroscopy should be employed more often in this hospital. Immediate gastrectomy is desirable for many but not all gastric ulcers. Carcinoma contained within the stomach may be cured by a reasonably safe procedure; carcinoma that has metastasized to lymph nodes is cured infrequently unless the involved lymph nodes *are in close proximity* to the primary tumor. Gastrectomy, partial or total, must be performed on the 10 per cent of patients whose lesion may be extensive within the stomach itself but without detectable spread elsewhere (Stout[54]). More stomach and more of the surrounding gastric bed should be excised than has been customary in previous years at this hospital. Total gastrectomy should be employed more often. A thoracoabdominal incision should be employed more frequently. Frozen-section diagnosis is occasionally necessary to determine that the margins of the resected gastric specimen are free of tumor, total gastrectomy being required when such margins are not obtainable. The entire greater omentum should be excised, thus ensuring removal of lymphatic structures along the greater curvature of the stomach. Excision of the lesser omentum should be generous; however, in the experience at this hospital, complete dissection along the porta hepatis or around the celiac axis would be too dangerous, with small promise of lasting cure if metastases had already occurred to lymph nodes at this distance from the primary tumor. A generous amount of duodenum or esophagus should be removed for tumors grossly in proximity to the pylorus or the cardia. A wide circle of lymphatic structures in proximity to the primary growth must be excised — patients in whom diffuse lymph-node metastases have already occurred are rarely cured; extensive dissection in the effort to excise all the nodes grouped about the celiac axis and origin of the left gastric artery, along the superior border of the pancreas and toward the hilus of the spleen, beneath the pylorus and around the head of the pancreas, distinctly increases the hazard of gastrectomy. More total gastrectomies on the bulky or diffusely spreading carcinoma are indicated; both the spleen and the left half of the pancreas should probably be included in such an excision, but this extensive operation should be re-

quired in less than 25 per cent of all cases at this hospital. So-called "compound gastrectomy" for the occasional locally invasive carcinoma involving adjacent resectable structures such as the colon and the tail of the pancreas offers the best palliation, and rare cases may be cured.

Precursors of Gastric Carcinoma

Results of surgical treatment of obvious carcinoma are poor. Hence, early detection and treatment of acknowledged precursors of gastric carcinoma (polyps, anacidity, with or without pernicious anemia, and gastritis, particularly atrophic) are imperative. Gastric ulcer is not listed as a precursor because I believe that carcinoma rarely develops in a benign ulcer.

Gastric Polyp

This lesion provides excellent opportunity for prophylactic surgery as demonstrated by A.S., aged sixty, in whom x-ray examination demonstrated a benign gastric polyp in 1939. Gastric acidity was not determined. Seven years later gastrectomy was performed for extensive carcinoma. It seems probable that the lesion was only a benign polyp seven years earlier. Patients with gastric polyps are frequently achlorhydric. In the experience of Marshall and Uram[55] 35 per cent of gastric polyps have proved to be malignant on microscopical examination.

Pernicious Anemia

Only 1 patient with long-standing pernicious anemia with anacidity in whom gastric carcinoma supervened was encountered The incidence of carcinoma in patients with pernicious anemia ranges around 10 per cent. Certainly, periodic x-ray examination of such patients twice a year would be ideal. Any localized proliferation of mucosa or irregularity would call for additional procedures such as cytologic and gastroscopic examination. Prompt resection of the distal two thirds of the stomach is indicated on early evidence of abnormal epithelial proliferation, without further delay for more accurate preoperative diagnosis, which might entail additional months of delay.

Gastritis

In 3 patients a diagnosis of diffuse gastritis had been made on x-ray study eighteen to twenty-four months before gastrectomy for proved carcinoma. Atrophic gastritis should arouse more concern than the hypertrophic form. Judd[56] has described changes indicative of severe chronic gastritis, with ultimate atrophy of the mucosa and diminished to absent acidity, in frequent association with carcinoma. Atrophic gastritis signifies parietal-cell atrophy in the mucosal layer and not interstitial lymphocytic invasion. Diminished or absent acidity is frequently found. Gastroscopy with biopsy is of considerable value, according to Benedict.[57] Wangensteen[52] estimates that gastric carcinoma has exisited for about twenty months before appearance of symptoms. Thus, adequate observation of all patients with atrophic gastritis may permit earlier recognition of still localized carcinomatous degeneration in occasional cases.

The Ulcer — Cancer Problem

Two alarming experiences with small ulcers along the lesser curvature in young patients were emphasized in the first part of this study. It is obvious that immediate gastrectomy should be performed on more patients in this hospital. Nevertheless, the decision for operation must be made on an individual basis in the particular patient according to the characteristics of his ulcer (size, location, duration, acidity and response to brief treatment) and available facilities (the surgeon, the anesthetist, the operating room and the mortality in the local hospital). At the Mayo Clinic it has been found that "the small gastric carcinoma with features suggestive of benign gastric ulcer has the best prognosis after gastric resection."[58]

At the annual meeting of the American College of Surgeons in November, 1954, Cooper[59] stated that cytologic study with the abrasive balloon had been accurate in 89 per cent of 400 cases. Benedict[57] reported that gastroscopic examination was helpful in 73 per cent of 184 ulcer-cancer problems. The availability of biopsies through the gastroscope has greatly increased its value. Pack[46] states that at the Memorial Hospital all the surgeons on the gastric service perform their own gastroscopies. Unfortunately, a great many smaller hospitals lack the service of a gastroscopist. Porter[60] recently gave a graphic illustration of the limitations of gastroscopy: "the gastroscopic view is like looking through a yard-long keyhole."

Difficulty in diagnosis and management of ulcerations located high in the stomach was illustrated by a patient who underwent a prolonged convalescence after total gastrectomy for a large proximal gastric ulceration. Since it was not possible to determine the benign nature of the ulcer at operation, the surgeon performed total gastrectomy. In 100 similar cases, Harvey[61] has inserted a sigmoidoscope into the stomach, obtaining multiple biopsies around the ulceration; he reports only 3 errors in these 100 cases. If such a relatively inaccessible ulceration can be demonstrated to be benign, a distal partial gastrectomy (Madlener) may be done with anticipation that even such a large ulcer will heal. Colp[62] expresses his preference for a distal gastrectomy, especially when the patient is a poor risk. There can be little doubt that cardiectomy is the more desirable procedure when the patient's condition and the surgeon's competence permit it.

In my opinion a gastrectomy should be performed in at least 50 per cent of cases at this hospital (present rate, 22 per cent.)

Lymph-Node Metastases

The most important factors determining long survival are the percentage of resectability in a group of cases and the presence of lymph-node metastases in individual cases. Lymph-node metastases were not found in 4 of 5 patients surviving over five years. A limited sleeve resection of the midportion of the stomach had been done in 1 of these cases because of age (eighty years). Neither vascular invasion nor lymph-node involvement was found. Welch[63] considers that the prospect for cure is slight, once metastases have occurred, regardless of the extent of lymph-node excision. Nevertheless, painstaking excision of a generous amount of lymph-node-bearing tissue from readily accessible areas in proximity to the primary tumor is essential. Welch and Allen[45] cite a five-year cure after only local excision because of early discovery of metastasis in an adjacent lymph node. This experience emphasizes the fact that localized carcinoma occasionally may be cured without heroic surgical effort if neither blood-stream invasion nor *distant* lymphatic metastases have occurred. Unfortunately, metastases in proximity to or remote from the primary tumor have already occurred in 85 per cent by the time of operation.[63]

Stout and Horn,[64] in their study of 143 autopsied cases, demonstrated that 10.5 per cent of carcinomas without previous gastrectomy had neither metastasized nor extended outside the stomach wall. The surgeon must remember this fact when confronted by an extensive tumor within the stomach but without evidence of surrounding invasion or metastases.

Expanded, Subtotal Gastrectomy

McNeer et al.[64] state, "Many surgeons who perform subtotal gastrectomy for duodenal ulcer apply erroneously the same technic to treatment of gastric cancer." Ochsner[65] has referred to many gastrectomies as "good-sized biopsies." He emphasizes the need of accurate definition of subtotal gastrectomy for carcinoma in contrast to the subtotal gastrectomy for ulcer. The earlier operative records at this hospital reveal the limited extent of many gastrectomies. Ochsner and Blalock[66] propose the term, "radical subtotal gastrectomy." In one sense the terms *radical* and *subtotal* are contradictory; in most organs the adequate operation implies total removal of an organ. They define the extent of the radical subtotal gastrectomy as the removal of all the first portion of the duodenum and all the lesser curvature up to the cardia; removal of all the greater omentum up to within 5 or 6 cm. of the cardia; removal of all the gastrohepatic omentum, the gastrocolic omentum and the greater omentum; and careful dissection of and removal of the lymph nodes along the lesser curvature, especially those around the celiac axis and left gastric vessels, the subpyloric nodes, the subhepatic nodes, the gastrolienal nodes and the paraesophageal nodes. The stomach is extensively resected, only a small remnant of cardia being left. With the exception of the cardia, there is no difference between this operation and total gastrectomy so far as completeness of dissection of perigastric lymphatics is concerned. Some surgeons perform routine total gastrectomy for all gastric carcinomas.[67-69] Others[46,70] prefer subtotal gastrectomy for carcinomas grossly contained in the distal third of the stomach, reserving total gastrectomy, splenectomy and partial pancreatectomy for carcinomas located in the middle or proximal third. Sweet[71] seriously considers this more extensive procedure for all cases of obvious carcinoma. It is important to appreciate that these extensions of the previous standard subtotal gastrectomy, advocated within the past decade, are not merely linear extensions of the operation involving only the removal of more of the stomach but circular expansions in the endeavor to encompass more lymphatic structures or adjacent resectable organs to which the carcinoma may have spread.

The Stomach

Margins of resection were not sufficiently far away from the gross extent of the tumor in many of the cases in this series, although more adequate margins were resected in the latter half of this study. Allen[72] seeks a margin of 5 cm. In most cases it is possible to make a reasonably accurate estimate of the gross extent of the primary tumor. In about 15 per cent of tumors of the superficial, spreading variety "cancerization of the mucosa"[73] or diffuse submucosal spread may not be readily detected by the surgeon's eye or finger. Some years ago Allen proposed that frozen sections were useful to confirm the absence of tumor at the margins of resection. However, Marshall and Uram[55] recently observed that microscopical examination of frozen-section material from the gastric or duodenal wall may not be too reliable. Figure 4 demonstrates that about 70 per cent of carcinomas are located in the distal third of the stomach. The lymphatic drainage from the stomach is cephalward with the exception of tumors located close to the pylorus. Carcinoma rarely invades the duodenal wall for a greater distance than 2 cm. Therefore, an adequate margin of normal proximal stomach or duodenum is usually available without cutting across invaded lymphatic channels. Much of the dispute about routine or frequent total gastrectomy revolves about this degree of spread of carcinoma within the gastric wall. McNeer et al.[64] concluded that cancer had been left behind in adjacent stomach wall in 50 per cent of 96 collected cases coming to autopsy at some time after subtotal gastrectomy had been done with the hope of cure. Residual carcinoma was demonstrated in the duodenal stump in 10 per cent and in resectable perigastric nodes in an additional 20 per cent. Thus, failure of local control of carcinoma was demonstrated in 80 per cent of these collected autopsies on postoperative patients.[46] There is little dis-

pute about the disheartening frequency of lymph-node metastases at the time of operation. There is, however, much less agreement about the frequency of residual carcinoma in the gastric wall after an apparently adequate subtotal gastrectomy. Allen,[72] Stout[84] and Walters et al.[74] maintain that persisting carcinoma encountered at autopsy after gastrectomy was rarely found within the remaining stomach but rather in the surrounding gastric bed. Stout found such persisting carcinoma in the stomach remnant in only 4 of 32 cases.

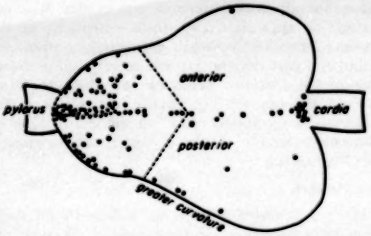

FIGURE 4. *Location of Carcinomas in 120 Gastric Resections (Reproduced from Stout[84] with the Permission of the Publishers).*

In some cases at Salem Hospital the stomach was so extensively involved that margins of 5 cm. were not available unless total gastrectomy had been done. In such cases there is now wide agreement about the desirability of total gastrectomy with generous excision of surrounding lymphatic structures, which can usually be carried out more readily if the initial epigastric incision is prolonged across the costal margin into the pleural cavity. It may be unnecessary to incise much of the diaphragm since in many cases the cardia and lower end of the esophagus may be adequately exposed by retraction of the divided costal margins.[55] It is interesting that in their study of the dimensions of surgical specimens from 60 patients surviving 5 years or longer after gastrectomy, Harvey et al.[39] could not determine statistically that it was important to keep the plane of excision a generous distance away from the growth within the stomach; in 18 cases the line of excision was less than 2 cm. from the tumor. Yet they concluded that such narrow margins of excision could not be recommended.

The Omentum

There is no dissension about complete excision of the greater omentum. However, there is room for discussion about extent of removal about the lesser omentum, including dissection of the subhepatic lymph nodes around the porta hepatis and the celiac axis. A painstaking dissection is often difficult and dangerous, with little promise of lasting gain, if metastatic cancer cells have already lodged in these relatively inaccessible lymph nodes.

The Duodenum and Esophagus

Within the past decade increasing emphasis has been placed on the necessity of removal of adequate portions of esophagus or duodenum when the tumor is in proximity. These tumors invade the esophageal mucosa or the duodenal submucosa readily. It was not customary to remove a generous portion of the duodenum at this hospital during the first half of this period. Too often a narrow strip of duodenum beyond the pylorus was removed for carcinoma located in the distal third of the stomach in which the proximal line of transection was placed well above the tumor site. Similarly, when the primary location was high in the stomach, inadequate proximal margins had often been obtained. Cases not included in this study had been deemed inoperable because of the proximity of the tumor to the esophagus. Within the past four years portions of the esophagus have been resected in addition to the primary gastric tumor.

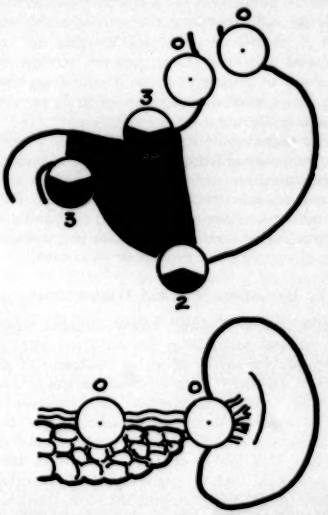

FIGURE 5. *Zonal Distribution of Lymph-Node Metastasis in 5 Cancers Arising in the Distal Segment — 2 Additional Patients Had No Metastases (Reproduced from Sunderland et al.[74] with the Permission of the Publishers).*

Lymph-Node Excision

The great frequency and wide dispersion of lymph-node metastases has been ably demonstrated[75,76] (Fig. 4-7). Sunderland et al.[76] showed that cancers of the

distal third of the stomach have spread principally to superior and inferior nodes along the curvatures of the stomach in addition to the subpyloric nodes, which are subduodenal and subpancreatic as well. Stout[64] points out that in carcinomas of the distal third of the stomach metastases to peripancreatic nodes lead to failure more often than invasion of the deeper layers of the duodenum.

Three other groups of lymph nodes challenging the surgeon's skill and the patient's survival are those around the left gastric artery and celiac plexus, the pancreaticolienal nodes along the superior border of the pancreas extending to the hilus of the spleen and the paracardial nodes encircling the upper end of the stomach. Lymph-node metastases are more frequent and more widely dispersed from cancers in the proximal and middle segments of the stomach.[76] McNeer[77] is convinced that metastases to the pancreas and splenic pedicle are so frequent in carcinoma of the proximal three quarters of the stomach that disease is *inevitably* left in the abdomen unless the left side of

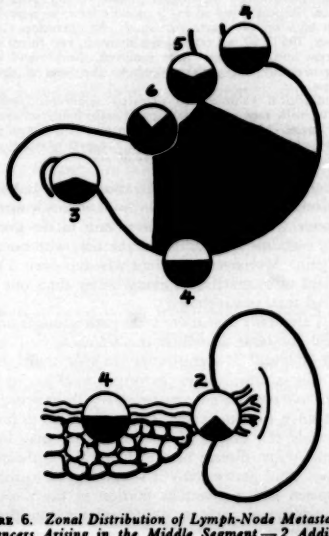

FIGURE 6. *Zonal Distribution of Lymph-Node Metastasis in 8 Cancers Arising in the Middle Segment — 2 Additional Patients Had No Metastases (Reproduced from Sunderland et al.[4] with the Permission of the Publishers).*

the pancreas and the spleen are removed with the stomach.

The five-year cure rate ranges around 50 per cent when no metastases to lymph nodes are detected but drops to around 10 per cent when nodes are involved. It has long been recognized that the stomach is a difficult organ on which to carry out a good cancer operation. It is virtually impossible to map out a procedure that will remove all involved lymph nodes. Hence, Wangensteen et al.[78] make a trial of their "second-look procedure." Persisting carcinoma in resectable lymph nodes was found in 22 of 39 patients at second operation (56 per cent). This "second look"

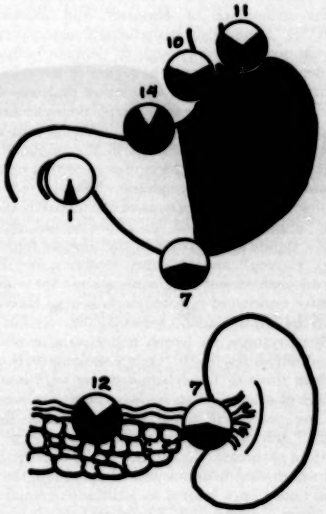

FIGURE 7. *Zonal Distribution and Number of Cases of Lymph-Node Metastasis in 16 Cancers Arising in the Proximal Segment (Reproduced from Sunderland et al.[4] with the Permission of the Publishers).*

is not as successful in gastric carcinoma as in carcinoma of the colon. Little reliance can be placed on the size of the lymph nodes as indication of metastases. In 1 of the 2 cases of thoracoabdominal total gastrectomy, splenectomy and pancreatectomy in the series at Salem Hospital no enlarged lymph nodes could be seen or felt at operation. Yet every one of twelve nodes dissected by the pathologist was replaced by metastatic carcinoma. Obviously, more lymph nodes will be removed in "radical subtotal gastrectomy" or compound total gastrectomy (including the spleen and pancreas). It is noteworthy that 3 early proponents of total or compound gastrectomy continue to advocate this vigorous surgical attack.[68,69,77]

However, the two factors of cure and risk must be balanced. These radical operations would be valid in this hospital only if carcinoma that had already invaded lymph nodes, some of which might be remote from the primary tumor, could be cured in a significant number of cases without prohibitive operative mortality. It is worthy of re-emphasis that lymphatic

drainage from the distal stomach is more difficult to excise than that from the proximal end. Resection of the duodenum and head of the pancreas would be required for an en-bloc removal of the subpyloric lymphatics. Block dissection of the pancreaticolienal nodes is not possible without pancreatectomy and splenectomy. Block dissection of lymph nodes around the celiac axis is difficult, dangerous and unrewarding in the experience of Harvey[39] and Welch and Allen.[45,79] Thrombosis of the hepatic artery and portal vein occurs often enough to dampen enthusiasm for energetic dissection in the region of the celiac axis and its radicles. It is my conviction that one should make greater effort to excise lymph nodes around the origin of the left gastric artery if the patient is not obese and if the carcinoma is in the proximal two-thirds of the stomach. It seems obvious that complete anatomic excision of lymphatic channels and nodes draining the various portions of the stomach is practically impossible. Such an effort would certainly cause a significant increase in the already high mortality. Harvey[39] and ReMine, Dockerty and Priestley[80] advance strong argument against the value of extensive excision of remote lymph nodes. Harvey reported that, of 60 patients surviving for over five years after gastrectomy, no lymph nodes were involved in 40, and only a few in 16. Only 4 patients were cured in whom three or more lymph nodes were involved. ReMine et al. state that, in 34 patients surviving for over five years, the metastatic nodes were located within 3 cm. of the nearest portion of the primary growth in each case. In another group of 34 patients, all of whom died within a year of operation, the metastatic nodes were located at a distance greater than 3 cm. from the primary in 83 per cent; the margins of the gastric remnant had been proved to be free of tumor by frozen section at time of operation.

Total Gastrectomy

Enthusiasm for routine or even frequent total gastrectomy appears to be diminishing. Marshall[81] sees no need of it for carcinoma located in the distal portion of the stomach. He stated recently that total gastrectomy at the Lahey Clinic has ranged between 20 and 30 per cent. Diffuse cancer, those extending high on the lesser curvature and tumors arising in the cardia require total gastrectomy, in his opinion. He believes that splenectomy should be performed in all cases of partial gastrectomy for carcinoma. Pack and Ochsner also urge a total gastrectomy for carcinomas located in the proximal portion of the stomach. Personal communications from Allen, Coller, Colp, Dunphy, Gray, Harkins, Longmire, Pack, Marshall, McNeer, McKittrick, Ochsner, Randall, Sweet, Wangensteen (Arhelger), Welch and Zollinger indicate that only 3 surgeons of this group propose total gastrectomy for all gastric carcinomas. Colp, Marshall, McNeer, Ochsner, and Pack employ total gastrectomy for carcinomas located in the proximal third or half of the stomach in addition to extensive tumors not removable by partial gastrectomy.

I appreciate that the spleen and a large portion of the pancreas must frequently be removed for tumors located in the proximal half of the stomach. Not only are such tumors located in a relatively silent area of the stomach, so that the cancer is larger and of longer duration when discovered, but also metastases to pancreaticolienal nodes are more frequent.

However, *partial* proximal gastrectomy, together with splenectomy and partial pancreatectomy, seems to be a more logical and a safer procedure for us. An adequate length of stomach and generous dissection of lymph nodes along both curvatures in the direction of the distal third may be done without compromise of circulation to the distal remnant. Obviously, total gastrectomy is indicated if metastases about the distal third of the stomach are suggested at operation.

A.K., a 65-year-old man, had been admitted twice to Salem Hospital because of profuse upper gastrointestinal bleeding. X-ray films 13 months before operation suggested the possibility of a small lesion on the posterior wall of the cardia. Gastroscopy was suggested but not accepted by the patient. Repeat x-ray study, 9 months later, suggested neoplasm high on the lesser curvature. At operation (in November, 1950) 50 per cent of the stomach, two thirds of the pancreas and the spleen were removed. End-to-end esophagogastrostomy was performed above the level of the diaphragm.

Pathological examination revealed undifferentiated carcinoma, with sheets of medullary growth, many mitoses and giant nuclei. Metastases were present in 1 of 9 lymph nodes. When last seen in December, 1954, the patient appeared to be in excellent health at 68 years of age.*

There was direct surface invasion of the tail of the pancreas. The margin of the distal stomach was free of tumor. Removal of the distal half of the stomach would certainly have added to the risk, with no probable gain. Moreover, a patient who has even a small remnant of stomach gets along better than one who has had total gastrectomy.

It is apparent that more total gastrectomies are indicated for cases in which the stomach wall is diffusely involved. It seems proper to state that the surgeon who is unwilling to perform a total gastrectomy *should not operate on any patient* with gastric carcinoma since, in many cases, it is not possible to predict accurately the extent of operation that may be required. When disease in the stomach is sufficient to warrant total gastrectomy it seems logical to include the spleen and a generous portion of the pancreas. Such additional excision would enlarge considerably the extent of removal of commonly involved lymph nodes without greatly increasing the danger to the patient.

Compound Gastrectomy

This is a convenient term to designate an operation in which stomach and adjacent invaded organs are excised en bloc. MacDonald and Kotin[73] advance

*Metastases to the liver were revealed at operation for intestinal obstruction (adhesions) in April, 1955.

the disturbing concept that more cures of gastric carcinoma are obtained in patients with symptoms of long duration. They employ the term "biological predeterminism," pointing out that final outcome is governed more by the type of growth than by the time or type of operation. It may be conjectured that bulky, locally extensive tumors that have spread through the stomach wall to invade adjacent structures have in a sense taken part in a biologic elimination in which absence of metastatic aggressiveness has been demonstrated by the size, long history and degree of local invasiveness. So-called superradical surgery, or compound gastrectomy, is certainly justified in the occasional patient since it offers the best form of palliation and some opportunity, although slight, for lasting cure. Brunschwig[82] recently called attention to the fact that in 3 of 4 patients who were living and well without evidence of disease over five years after operation, total gastrectomy with removal of the spleen and pancreas had been done. The truth of Dunphy's[83] comment is apparent: "These super-radical procedures in the hands of all but the most gifted surgeons will significantly increase mortality and morbidity."

Summary

A small series of 46 gastrectomies for gastric carcinoma is reported from a community hospital. The operative mortality for the fifteen-year period, which is high (31 per cent), has been reduced steadily to a reasonable rate during the past four years.

The five-year cure rate is only 4 per cent of all hospitalized patients with gastric carcinoma.

Certain personal opinions are expressed about the indications for and extent of desirable gastrectomy for carcinoma at this particular hospital.

References

45. Welch, C. E., and Allen, A. W. Carcinoma of stomach. *New Eng. J. Med.* 238:583-588, 1948.
46. Pack, G. What constitutes adequate operation for carcinoma of stomach? Presented at postgraduate course on surgery of the lower esophagus, stomach and duodenum at the annual clinical congress, American College of Surgeons, Atlantic City, New Jersey, November 11, 1954.
47. Kremen, A. J. Gastric carcinoma. Presented at a meeting of New England Cancer Society, Francis Delafield Hospital, New York City, December, 1954.
48. Welch, C. E. Personal communication.
49. Abrahamson, R. H., and Hinton, J. W. Gastric carcinoma: comparative review of origin, diagnosis, and end-results in 583 patients. *Surg., Gynec. & Obst.* 84:481-490, 1947.
50. Meissner, W. A. Malignancy of gastric cancer. *J. Nat. Cancer Inst.* 10:533-538, 1949.
51. Allison, P. R., and Borrie, J. Treatment of malignant obstruction of cardia. *Brit. J. Surg.* 37:1-21, 1949.
52. Wangensteen, O. H. *Cancer of the Esophagus and the Stomach.* 112 pp. New York: American Cancer Society, 1951.
53. McNeer, G., Sunderland, D. A., McInnes, G., VandenBerg, H. J., Jr., and Lawrence, W. More thorough operation for gastric cancer: anatomical basis and description of technique. *Cancer* 4:957-967, 1951.
54. Stout, A. P. *Tumors of the Stomach,* Section 6, Fascicle 21, 104 pp. Washington, D. C.: Armed Forces Institute of Pathology, 1953.
55. Marshall, S. F., and Uram, H. Total gastrectomy for gastric cancer: effect upon mortality, morbidity, and curability. *Surg., Gynec. & Obst.* 99:657-675, 1954.
56. Judd, E. S. Possible relation of residual lesions in gastric mucosa to development of carcinoma of stomach. Thesis, University of Minnesota Graduate School, 1938.
57. Benedict, E. B. Personal communication.
58. Comfort, M. W., et al. Small gastric cancer. *Arch. Int. Med.* 94:513-524, 1954.
59. Cooper, W. A. Differentiation of benign and malignant ulcers — studies in gastric cytology. Presented at the postgraduate course on surgery of the lower esophagus, stomach and duodenum at the annual clinical congress of the American College of Surgeons, Atlantic City, New Jersey, November 16, 1954.
60. Porter, M. Diagnosis of gastric ulcer. Presented at a meeting of the New England Cancer Society, Francis Delafield Hospital, New York City, December, 1954.
61. Harvey, H. D. Cited by Porter.[60]
62. Colp, R. Selection of operation for gastric ulcer. Presented at the postgraduate course on surgery of the lower esophagus, stomach and duodenum at the annual clinical congress of the American College of Surgeons, Atlantic City, New Jersey, November 16, 1954.
63. Welch, C. E. Personal communication.
64. McNeer, G., VandenBerg, H., Jr., Dean, F. Y., and Bowden, L. Critical evaluation of subtotal gastrectomy for cure of cancer of stomach. *Ann. Surg.* 134:2-7, 1951.
65. Ochsner, A. Personal communication.
66. Ochsner, A., and Blalock, J. Carcinoma of stomach: necessity for reevaluation of therapeutic philosophy. *J.A.M.A.* 151:1377-1384, 1953.
67. Lahey, F. H. Total gastrectomy for all patients with operable cancer of stomach. *Surg., Gynec. & Obst.* 98:246-248, 1940.
68. Longmire, W. P., Jr. Personal communication.
69. Coller, F. A. Personal communication.
70. McNeer, G. Cited by Pack.[46]
71. Sweet, R. H. Total gastrectomy by transthoracic approach: subsequent report. *Ann. Surg.* 138:297-310, 1953.
72. Allen, A. W. Personal communication.
73. MacDonald, I., and Kotin, P. Biologic predeterminism in gastric carcinoma as limiting factor of curability. *Surg., Gynec. & Obst.* 98:148-152, 1954.
74. Walters, W., Gray, H. K., and Priestley, J. T. Advances in surgical treatment of cancer of stomach. *Proc. Staff Meet., Mayo Clin.* 27:156-161, 1952.
75. Coller, F. A., Kay, E. B., and McIntyre, R. S. Regional lymphatic metastases of carcinoma of stomach. *Arch. Surg.* 43:748-761, 1941.
76. Sunderland, D. A., McNeer, G., Ortega, L. G., and Fearce, L. S. Lymphatic spread of gastric cancer. *Cancer* 6:987-996, 1953.
77. McNeer, G. Personal communication.
78. Wangensteen, O. H., Lewis, F. J., Arbelger, S. W., Muller, J. J., and MacLean, L. D. Interim report upon "second look" procedure for cancer of stomach, colon, and rectum and for "limited intraperitoneal carcinosis." *Surg., Gynec. & Obst.* 99:257-267, 1954.
79. Allen, A. W. Ulcer and cancer of stomach. *Kentucky M. J.* 50:325-330, 1952.
80. ReMine, W. H., Dockerty, M. B., and Priestley, J. T. Some factors which influence prognosis in surgical treatment of gastric carcinoma. *Ann. Surg.* 138:311-319, 1953.
81. Marshall, S. F. Personal communication.
82. Brunschwig, A. Five-year survivors following pancreato-spleno-total gastrectomy for "advanced" cancer of stomach. *Ann. Surg.* 141:62-69, 1955.
83. Dunphy, J. E. Personal communication.

MEDICAL PROGRESS

DERMATOLOGIC THERAPY (Concluded)

JOHN GODWIN DOWNING, M.D.*

BOSTON

SUNBURN PREVENTIVES

Although cutaneous eruptions from sensitivity to sunlight were first discovered over a hundred and fifty years ago, interest in this subject is recent. The discovery of the photosensitizers, especially the porphyrins, twenty-five years ago aroused interest in systemic investigations of these cases. Undoubtedly, there is some particular sensitizing agent circulating in the blood of these patients. Why should people suffer from diseases ranging from a mild eruption like sunburn, urticaria, eczema and hydroa aestivale to serious cutaneous diseases such as chronic or acute lupus erythematosus, pellagra and pellagroid eruptions, keratoses and cancer in adults, and diseases like xeroderma pigmentosa in children?

It is known that certain drugs such as the sulfonamides, coal-tar derivatives, dyes and some barbiturates given parenterally sensitize the skin to sunlight. Most of these also produce photosensitivity when applied to the skin. Although most of these eruptions are temporary, there is always the danger that the serious disease, lupus erythematosus, may appear in the acute or chronic form.

The large number of skin diseases caused by sunlight, ranging from urticaria to cancer, should be prevented, if possible. Therefore, any substance that will protect the skin is valuable. The military authorities are especially interested in this problem to protect the armed forces. They have formulated definite specifications for sunburn preventives.

The action spectrum of sunburn erythema lies between 2900 and 3170 A. U. Compounds that possess the physical property of absorbing energy in this range have been investigated for their advantage in preventing sunburn. Kesten and Slatkin[32] found that ointments incorporating 15 per cent para-aminobenzoic acid and one containing 5 per cent cycloform (isobutyl para-aminobenzoate) offered excellent protection. Each of the following ointments afforded little protection: 5 per cent menthyl orthoaminobenzoate, 5 per cent of two parts menthyl orthoaminobenzoate and five parts ethylene glycol monosalicylate, 5 per cent "heliophan" (homomenthyl salicylate), 10 per cent "sunarome O" (2-ethyl-hexyl salicylate), 5 per cent "filtrosol A," and 5 per cent "filtrosol B" (salicylate family). Preliminary studies suggest that only a few sun screens and carbolated petrolatum protect the skin from half the erythemic radiation (10 minimal erythema doses) that might fall on a person on any given day.

Harber[33] designed experiments to evaluate the sun-screening properties of a group of 5 compounds containing the substituted benzoic acid nucleus. The compounds were tested for their capacity to prevent erythema caused by exposure to the Hanovia direct-current ultraviolet lamp and to natural sunlight.

Although all compounds tested exhibited erythema-preventing properties both tannic acid and para-aminobenzoic acid were superior to all other agents tested. The superiority of tannic acid was particularly evident when comparisons were made on an equimolar basis. Para-aminobenzoic acid was almost as effective as tannic acid in preventing erythema when tested in equipercentage solutions.

Under rigid statistical analysis, no significant differences could be established in the sun-screening properties of phenyl salicylate, menthyl anthralinate or glyceryl para-aminobenzoate.

For popular use these preparations must give protection but at the same time allow their users to develop a tan. They must not stain textile fabrics, and they must not be too greasy.

I have tried many compounds, several of them formulated with members of the staff of the Massachusetts College of Pharmacy. In my experience an excellent nongreasy preparation is as follows:

Tannic acid	6
Salol	1
Castor oil	5
Water	5
Alcohol	83

This compound allows the skin to obtain a certain amount of tanning. The following is another excellent formula:

Para-aminobenzoic acid	15
Vanishing cream base	qs 100

However, I have seen a few cases of dermatitis from the local use of para-aminobenzoic acid.

Iodine, which is an ingredient of some sun-screen lotions, may cause an extensive, serious eruption in those allergic to iodine.

With the increasing vogue of sun-bathing and outdoor activities, light sensitivities are frequent. Therefore, any substance that will increase tolerance to sunlight should be a boon. It was found that the use of quinacrine hydrochloride prevented recurrences

*Professor of dermatology emeritus, Boston University School of Medicine and Tufts University School of Medicine.

in a person previously a victim of light sensitivity. Later chloroquine proved more effective and caused fewer side effects. Knox et al.[34] present data on 18 patients with various types of solar dermatitis who were treated by different investigators with quinacrine or chloroquine. The dosage varied, but improvement was noted in all the patients with light-sensitive eruptions. Chloroquine diphosphate has a somewhat similar chemical structure to quinacrine, although it has one less benzene ring. Even though this chemical does not produce fluorescence as quinacrine does, it appears to be equally beneficial in both lupus erythematosus and solar dermatitis. The amount of these agents required to prevent actinic dermatitis probably varies in each case. It is hoped that small amounts or even traces may be sufficient in these eruptions. As yet nothing seems to explain all the factors in the beneficial effect of these drugs on patients with actinic dermatitis.

Cahn, Levy and Shaffer[35] treated 16 patients with the prurigo-aestivalis type of polymorphous light eruption. Chloroquine diphosphate or quinacrine hydrochloride were administered in the spring and early summer of 1953, when the eruptions were at their height. After the disappearance of the eruptions under medication, 14 of these patients had no recurrences for the remainder of the summer months despite unrestricted exposure to sunlight.

It has been found that chloroquine can be added to ordinary salt and that it is not affected by cooking. It is now being shipped to remote areas in Brazil to help prevent malaria.[36] Perhaps this salt mixture might be a good preventive against ill effects of sunlight on light-sensitive persons.

At a recent dermatologic session in Philadelphia, one of the younger dermatologists of that city was asked why he tried chloroquine (Aralen) phosphate on an incurable skin disease. His reply was that in Philadelphia it seemed to be the cure-all for most dermatologic diseases. Its success in many cases of chronic lupus erythematosus has been excellent. Pillsbury and Jacobson[37] treated 16 patients with chronic discoid lupus erythematosus by administration of chloroquine (Aralen) diphosphate in daily doses of 0.25 to 0.5 gm. Clinical effects were generally very good, equal or superior to those obtained with quinacrine (Atabrine) therapy.

During a period of observation varying from four to ten months after the initiation of chloroquine therapy, no significant toxic effects were noted. The absence of pigmentation, which is a highly objectionable feature of quinacrine therapy, is a great boon.

Harvey and Cochrane[38] state that, after quinacrine hydrochloride had proved effective in the treatment of lupus erythematosus, they decided to try other antimalarial drugs. They gave chloroquine sulfate to 10 patients with lupus erythematosus and proquanil hydrochloride to 10 other patients with this disease. No response was obtained with the latter compound, but in 2 patients treated with chloroquine sulfate the lesions cleared completely. After this, chloroquine sulfate was used in 30 patients with chronic discoid lupus erythematosus. Tablets containing 150 mg. of chloroquine base were used throughout. For the first two weeks 150 mg. of chloroquine base was given daily. The dosage was then increased to 300 mg. daily for four weeks and reduced to 150 mg. daily for the next four weeks. Nine patients showed an excellent response to treatment, their lesions clearing or healing completely. Another 9 had a satisfactory improvement.

Tye et al.[39] treated 26 patients with chronic discoid lupus erythematosus with 7-chloro-4-(4-diethylamino-1-methylbutylamino) quinoline (chloroquine) in the phosphate form (Aralen phosphate). Four of these patients had previously been treated with Daraprim (2:4-diamino-5-[p-chlorophenyl]-6-ethylpyrimidine), with no objective evidence of improvement. Two dosage schedules were used. On the first dosage schedule, 13 patients were treated with 1 tablet (0.25 gm.) four times daily for two days, 1 tablet three times daily for two days and then 1 tablet twice daily; the dosage was then dropped in some patients to 1 tablet daily as the lesions cleared or were greatly improved. The remaining 13 patients (second dosage schedule) were given 1 tablet (0.25 gm.) three times daily for two weeks, 1 tablet twice daily for one week and then 1 tablet daily as a maintenance dose. In 13 (5 on the first and 8 on the second dosage schedule) the lesions completely cleared. The other 13 showed improvement continuing for six and seven months after institution of treatment. The greatest degree of improvement seemed to occur in the first month in some patients, and the rate of progress was slow but gradual for several weeks thereafter. There were recurrences in 3 patients, who were placed on maintenance therapy. Undesirable side effects were observed in 3 patients; 1 had headache after 3 tablets daily, another complained of nausea and dizziness while receiving 3 tablets daily, and a third had nausea, dizziness and diplopia after 2 tablets daily. All symptoms disappeared when the dosage was decreased.

Ayres and Ayres[40] state that chloroquine, tested empirically in several dermatoses, was effective in some cases of lichen planus and verruca but failed in others. The number of favorable responses in these two conditions was sufficient to encourage further investigation, but the number of patients treated was far too small for statistical evaluation. The drug was of no benefit in psoriasis. It appeared to exert an antipruritic or anti-inflammatory effect in a few cases of pruritic and eczematous dermatoses of various types. Chloroquine caused a severe dermatitis medicamentosa in 3 patients and a less severe eruption in 1.

Rogers and Finn[41] list some of the side effects of chloroquine. In preliminary trials with 0.25 gm. twice daily, some patients complained of blurring of vision. However, on 0.25 gm. daily the side effects were seldom of such magnitude as to interrupt treatment. Isolated cases of headache, nausea, giddiness and abdominal pain were noted.

Fonzari,[42] in Brazil, reports his experience in a five-year period with quinacrine hydrochloride in the treatment of 151 patients with pemphigus foliaceus. Of these, 87 reached the regressive stage, and 6 became free of progressive lesions. When the regressive stage is reached, the administration of the drug may be discontinued, the disease going on by itself to a clinical cure. Only 17 patients showed toxic effects, the most serious being psychosis in 3 and lichen planus in 1. All these effects were reversible. Of 18 patients who died, in only 4 would it have been possible to suspect a toxic action of quinacrine on the heart.

Farber and Driver[43] state that the mode of action of quinacrine may be explained in one of three ways: by a reduction in light sensitivity of the skin, by an action similar to that of ACTH and cortisone or by antagonizing adenyl compounds in the lesions of chronic discoid lupus erythematosus.

Fungicides

Many new remedies have been introduced for the treatment of fungous diseases. A few have shown themselves to be of some value, but many have been useless and even harmful. Ungerman and Ungerman[44] report 2 cases of cerebral intoxication in children suffering from microsporia and treated by local application of a 5 per cent asterol dihydrochloride tincture and an ointment containing 5 per cent salicylic acid and 10 per cent sulfur. Nine days after institution of treatment visual and auditory hallucinations occurred; the children were apathetic, disoriented and finally somnolent, and the younger patient had tonic and clonic spasms in addition. Encephalographic findings suggested a cerebral disturbance. Neurologic symptoms disappeared, without special treatment, within a few weeks of discontinuation of cutaneous treatment. It is contended that the symptoms were attributable to asterol, since salicylic acid primarily gives rise to gastrointestinal disturbances, which were lacking in these cases. It is pointed out that asterol should not be used unless under careful control, particularly in the treatment of children.

Infections of the skin due to *Trichophyton rubrum* are most difficult to relieve. Most cases show a dry, scaly eruption on the skin, frequently on the palms and soles. The nails are often involved, with destruction of the nail tissue. Thompson[45] reviews observations on 39 patients with ringworm of the skin of the hands and fingernails caused by *T. rubrum*. Nearly all patients complained of pruritus of the hands, together with stiffness and dryness. The results of therapy were disappointing, although most patients were co-operative and diligent in carrying out the prescribed treatment. Seventeen patients used a routine consisting of the inunction of 3 per cent thymol, salicylic acid and benzoic acid in aquaphor at bedtime and sleeping with thin cotton gloves covering the hands. Infected nails were filed daily. Only 3 of these patients are known to have negative cultures and clinically well hands. Twenty-two patients followed the same routine except that 1,8-dihydroxyanthranol ointment was used, starting with a concentration of 0.1 per cent and increasing to 0.25 per cent and even 0.5 per cent as tolerance developed. Six of these patients are believed to be well.

Wooldridge[46] clinically tested a new fungicide — 2-nitro-2-bromo-1-methoxy-1-phenyl-propane. Eighty-one patients with mycotic infections of the glabrous skin were treated with a vanishing-cream-type base containing 1 per cent of the new fungicide. Of 48 *T. rubrum* cases (without nail involvement) 33 were cured, 12 were improved, and 3 were unimproved. The treatment period was three to thirteen weeks. No primary irritation or allergic reactions were seen, but a 2 per cent concentration proved to be mildly irritating in some cases. Secondary infections were no contraindication to the use of the new compound. The fungicide is considered of greatest value in the often recalcitrant *T. rubrum* infections.

In 1953 Rothman[47] reported the disappearance of onychomycosis due to *T. rubrum* in 3 of 9 patients after prolonged treatment with lithium bromide, a solution of glucose and asterol (2-dimethylamino-6-[B-diethylaminoethoxy]-benzothiazole) dihydrochloride and a nail lacquer containing lithium bromide and asterol base. Kesten et al.[48] used this technic in 32 patients with *T. rubrum* infection, with cure in 2 cases and definite improvement in 19.

In the past year in private practice I have seen more cases of tinea capitis in children than in any previous years. These patients have had many months of varied treatments, and all the parents have refused to allow x-ray epilation. These cases present a difficult problem to the physician because a successful result depends on thorough co-operation of the parent. The patients eventually get well, but this means a protracted period of medical observation and in some areas children are unnecessarily excluded from school. Therefore, continued efforts are made to find a good fungicide.

Rosenthal et al.[49] tested ointments containing 2 and 5 per cent concentrations of Di-Paralene (chlorocyclizine hydrochloride). These were prepared for topical application in the standard *U.S.P.* hydrophilic petrolatum. As a control, gauze patches impregnated with Di-Paralene were applied for forty-

eight hours to the inner surface of the forearm of 197 volunteers. No local reactions were noted after the removal of the patch. This ointment was evaluated in 29 children with tinea capitis. Of 15 children treated with 2 per cent Di-Paralene ointment, only 2 could be classified culturally and clinically as cured. Of 14 children treated with 5 per cent ointment, 11 showed an initially favorable response, but only 6 were classified as cured.

It has always been my opinion that a good copper compound will be the answer to fungous infections. A copper undecylenate was apparently encouraging in the treatment of a series of cases of ringworm of the scalp.[50]

Blastomycosis, although rare, can occur in New England.[51] It can be a serious disease involving the skin, lungs and bones. Sutliff, Kyle and Hobson[52] state that stilbamidine and 2-hydroxystilbamidine are an improvement over former treatment of the systemic type of North American blastomycosis. They advise caution in the use of these drugs.

Isoniazid

In 1912[53] two German chemists produced isonicotinic acid hydrazide, which is now called isonicotinyl-hydrazine or isoniazid. In 1945 two Frenchmen, Huant and Chorine, presented separate reports on the antituberculous activity of nicotinamide. The action of this substance against the tubercle bacillus was rediscovered by two Americans, McKenzie and Kushner, in 1948. In trials of isoniazid in pulmonary tuberculosis the earliest clinical investigators gave this drug alone to several patients with advanced and therapeutically unresponsive disease. They observed x-ray, clinical and laboratory improvement, consisting of lessened cough, lowered temperature, improved roentgenologic findings, decreased Gaffky counts, some negative sputums and increased weight.

The first report on the use of isoniazid therapy in cutaneous tuberculosis came from Bonn, Germany, where several previously unresponsive patients with tuberculosis cutis of the luposa, verrucosa, colliquativa and papulonecrotica types attained good healing and had no untoward reactions with oral administration of doses of 5 to 10 mg. per kilogram of body weight per day.

The effect of isoniazid therapy was studied by Holsinger and Dalton[53] in 8 cases of tuberculosis cutis, including 3 of the luposa, 1 of the colliquativa, 2 of the papulonecrotica and 2 of the micropapular type of this disease, and in 2 additional cases of sarcoidosis. In the true tuberculoderms 2 patients with tuberculosis cutis luposa and 1 with tuberculosis cutis colliquativa obtained excellent therapeutic results with isoniazid administered alone or in combination with streptomycin or dihydrostreptomycin. However, another patient with tuberculosis cutis luposa showed an incomplete response to isoniazid and dihydrostreptomycin. In the last 2 cases of tuberculosis cutis papulonecrotica 1 patient had prompt and complete disappearance of his lesions with isoniazid combined with dihydrostreptomycin, and the lesions remained clear after discontinuance of therapy. The condition of the other patient has worsened during treatment with isoniazid combined with streptomycin and para-aminosalicylic acid. Of the 2 patients with micropapular tuberculid both showed a slow response to isoniazid therapy alone, but when last seen they were showing definite signs of improvement and the skin of one of them was essentially clear. In the 2 cases of sarcoidosis there was no cutaneous improvement after administration of isoniazid alone.

Erythema induratum (tuberculosis indurativa), a persistent nodular eruption of the legs in young women, is very resistant to treatment. Pasieczny[54] reports on 10 women between nineteen and fifty-three years of age who were treated with streptomycin and isoniazid. These cases were selected from a larger group, which may be clinically similar (erythema nodosum and nodular vasculitis, with a duration varying from six months to nine years). The distribution of the lesions was typical in 6 cases; in 3 there was a wider distribution, involving the thighs and buttocks in addition. In 1 case only one leg was involved. Full-scale physical examinations and blood investigations revealed no abnormalities. The biopsy in each case showed the typical histologic appearance associated with erythema induratum. All patients were treated as outpatients. All cases had previously been given various ointments, ultraviolet-lamp therapy and a vitamin K preparation (tablets Synkavite), and 1 received penicillin injections and para-aminosalicylic acid. From the 10 cases treated, an excellent initial response was obtained in 9 and moderate improvement in 1.

Cotinazin, a brand of isoniazid, was given by mouth to 7 patients with chronic lupus erythematosus in doses of 50 mg. three times a day. The effect was similar to that in patients with tuberculosis—namely, a marked tonic and alterative effect. Isoniazid was given to 7 patients with chronic lupus erythematosus, of whom 2 had disseminated and 5 discoid lesions. In only 2 cases was there definite objective improvement; this was not, however, of any remarkable degree.[55]

Cormia et al.[56] gave isoniazid (Nydrazid) to 7 patients with lupus vulgaris, to 2 with scrofuloderma, to 15 with tuberculid, to 7 with leprosy, to 4 with sarcoid and to 14 with miscellaneous conditions. The drug had a decidedly beneficial effect in all 9 cases of lupus vulgaris and scrofuloderma. The response of tuberculid to therapy was poor in 11 cases, excellent in 3 and satisfactory in 1. In 3 cases of lepromatous and one of indeterminate leprosy, the disease responded satisfactorily after three to four months of

continuous therapy. There was no response in 3 cases of tuberculoid leprosy. The drug was not of benefit in 4 cases of sarcoid, 3 of dermatitis herpetiformis (Duhring's disease), 7 of chronic discoid and 1 of chronic disseminated lupus erythematosus.

Therapy for Psoriasis

What apparently helps 1 patient with psoriasis is a failure with the next. Several pancreatic extracts have been tried in recent years, with varying success. Some of the patients have felt better, but there is not sufficient evidence to recommend such therapy. Occasionally, a patient became worse under medication. The 1954 literature contains over a hundred kinds of treatment for psoriasis. Only one writer[57] reported that a drug was valueless — glucuronic acid. This drug had been given a therapeutic trial in 6 patients with psoriasis vulgaris. Except for 1 patient who showed diminished scaliness five weeks after treatment, there was no favorable response.

Ingels[58] reported on 24 patients with psoriasis treated with Entozyme, a pancreatic extract. The disease had been recalcitrant to all previous treatment. In 4 cases good response was observed after four weeks of treatment, and the cholesterol content of the blood was below 300 mg. per 100 cc. In 15 cases there was good response after longer periods of treatment, up to three months; in 7 of these cases the cholesterol content was below 300 mg., and in 8 it was 300 mg. per 100 cc. or above. In 4 cases in which good response occurred the skin cleared completely and the blood cholesterol was below 300 mg. per 100 cc.

When a new drug is introduced, it is rapidly tried on many conditions unrelated to the original disease for which it was found to be of value. Eventually, everything is tried in cases of psoriasis. Rein and Goodman,[59] in an attempt to evaluate the efficacy of reserpine, a pure crystalline alkaloid of *Rauwolfia serpentina*, a small shrub indigenous to India, gave 60 patients an average dose of 0.25 mg. four times daily for a month. Forty patients experienced definite relaxation and tranquillization and slept better. Side effects, which included nasal congestion, increased appetite, depression, dreams, nocturia, dyspnea, weakness and nausea, made it necessary to discontinue therapy in 10 patients, who were not included in the total of 60 evaluated. Of 30 patients maintained on placebo therapy, in 22 there was evident diminution in relaxation or sedation and a lessening of the side effects. No significant blood-pressure or pulse change was noted in this essentially normotensive group. Five patients with hyperhidrosis experienced moderate improvement while taking reserpine. Rein and Goodman believed that its tranquillizing qualities in patients with dermatoses affected by a psychogenic or emotional tension factor make it another valuable aid for the armamentarium of the dermatologist. I tried Serpasil on 10 patients, but stopped it when 2 patients with a mild psoriatic eruption manifested a generalized psoriasis.

I have advised physicians to be careful in prescribing Thorazine (chlorpromazine hydrochloride) in the treatment of patients with cutaneous eruptions. Two recent reports confirm this statement. One[60] suggests caution in the follow-up study of patients treated with this drug.

The other[61] reports 24 cases, the average dose being 400 mg. a day given orally or intramuscularly. Two of these patients showed clinical jaundice, which rapidly disappeared after discontinuance of the drug. In 3 patients an itchy, erythematous, papular eruption developed on the trunk and upper and lower extremities. Itching was pronounced, and urticarial wheals appeared after scratching (dermographism). One patient, whose skin was ordinarily more sensitive to the sun, manifested marked redness of the face, neck and dorsal surfaces of the hands, and edema developed under her eyes after exposure to the sun and after she had been on Thorazine for two weeks. One patient had a slight edema of the face after exposure to the sun and after she had been on the drug for two weeks (photosensitization effect?).

Tar given locally and ultraviolet radiation, combined with reassurance, are still the therapy of choice for most patients with psoriasis.

Miscellaneous Conditions

Selenium sulfide emulsion has acquired considerable popularity as a shampoo in the relief of persistent seborrhea of the scalp. An ointment of 1 per cent selenium sulfide was tried by Ayres and Ayres[62] for the treatment of seborrheic dermatitis. They advised caution in its use. A 1 per cent solution aggravated the eruption, and with 0.5 per cent there were few cases of irritation.

I recently saw 2 cases of acute dermatitis of the scalp that followed the use of a shampoo containing selenium sulfide. This only proves that every drug is potentially allergenic to some person.

Tronstein[63] states that although certain of the oxyquinoline derivatives, such as Vioform and Quinolor compound, have been known to be useful as topical therapeutic agents in pyodermas and related conditions, the dichloroxyquinaldine products are not so well known in this country. He states that dichloroxyquinaldine (Sterosan) appears to be a satisfactory addition to the field of topical therapy in dermatology. It is of greatest usefulness when employed in conditions in which infection by gram-positive, actively reproducing micro-organisms either is the specific etiologic agent or plays a major part. In Tronstein's experience it appeared to be less sensitizing than a related oxyquinoline derivative, 5-chlor-7-iodo-8-hydroxyquinoline (Vioform).

I have found it to be of value in a few cases of otitis externa.

Lubowe[64] clinically evaluated a new local anesthetic, hexylcaine (Cyclaine) hydrochloride (1-cyclohexylamino-2-propylbenzoate) in 258 cases of pruritic dermatoses. Satisfactory relief was obtained in 220 patients. In 38 patients relief was temporary. Patch tests of the hexylcaine preparations on 200 patients, selected with no known sensitization to external contactants, revealed no primary sensitization or secondary allergenic response. No cross-sensitization exists between hexylcaine and patients who are sensitive to ethyl aminobenzoate (benzocaine) or paraphenylenediamine. Hexylcaine ointment and lotion were said to have an extremely low sensitization index.

In a brief trial of an ointment containing hexylcaine hydrochloride, I encountered 2 cases of severe sensitization dermatitis.

Several years ago the sulfonamides were condemned as topical applications. Duemling[65] apparently believes that there must be some sulfonamides that can be used locally. The chemotherapeutic effectiveness of a new sulfonamide (sodium sulfacetamide) was studied in the management of 100 patients, of whom 76 had seborrheic dermatitis of varying extent and severity; 24 had other dermatoses, including primary bacterial cutaneous infections. Four cases of irritation were encountered. Two patients reacted to a 30 per cent solution instilled into the eyes, 1 to a shampoo, and 1 to the ointment. Of the 76 cases of seborrheic dermatitis 46 were completely controlled in two weeks to six months. Twelve patients used only a shampoo containing 3 per cent sodium sulfacetamide, and the remainder a 10 per cent sodium sulfacetamide ointment for varying lengths of time, finally completing their treatment with the shampoo alone. Improvement was striking in cases complicated by secondary bacterial infection, oozing and crusting. Of the 24 cases comprising other dermatoses complete control was achieved with the use of 10 per cent sodium sulfacetamide ointment in 17.

Four per cent, although not a high rate of irritation, is still too great for any trial test of a sulfonamide. There have been too many severe cases of sensitization from the other sulfonamides.

Parish[66] treated 73 unselected patients with poison-ivy dermatitis with Prantal, a quarternary amine. The drug was given by mouth daily in divided doses until complete disappearance of the lesions occurred. Topical therapy was not employed, although some patients had used various lotions or creams before reporting for treatment. Relief of pruritus was reported by some patients eight to twelve hours after the start of medication and by all patients within twenty-four hours. Diminution of weeping was frequently reported at twenty-four hours and was generally complete at the time of the first follow-up examination (forty-eight to seventy-two hours). The lesions cleared completely in an average of five days (range, three to eight days). A more rapid result was noted in the adults taking 400 mg. daily than in those taking 300 mg. daily.

The relief of pruritus afforded by Prantal decreases the urge to scratch and thereby helps to promote healing of the lesions and minimizes the risk of secondary infection, especially in children. The manner in which Prantal exerts its antipruritic effect is unknown. Perhaps this effect is mediated through the cholinergic blocking action of the drug. I have found an ointment containing Prantal to be of value in a few cases of persistent vesicular eruption of the palms.

Localized hyperhidrosis (excessive sweating) can be a distressing affliction. Many local and systemic remedies have been tried, with varying success. Mild cases respond to local applications of aluminum acetate or chloride. X-ray therapy has had good results. Before Prantal, atropine and its derivatives and methaneline (Banthine) were tried, with some success,[67] but for the most part results have been only temporary. I have seen 4 patients who had been so annoyed by excessive sweating that they submitted to sympathectomy, with excellent results in 2 cases and dissatisfying results in the other 2. However, sympathectomy is a serious procedure necessitating prolonged hospitalization. A recent report[68] states that chemical sympathectomy with 95 per cent alcohol in lieu of surgery was used effectively to control hyperhidrosis in patients who had been refractory to a medical regimen of treatment.

Herpes simplex (fever blister or cold sore) is a mild, self-limited eruption in most cases. If, however, this eruption appears frequently in the same area, usually a conspicuous one on the face, or in an annoying spot such as the penis, a patient is very anxious to obtain permanent relief. The best relief to date has been obtained from immunization with smallpox vaccine, after careful examination for disturbances that might provoke the eruption has been made in vain. Undoubtedly, in many cases, there is a family tendency to the viral infections, which do not lead to any lasting immunity. Schiff and Kern[69] treated 68 cases with multiple smallpox vaccinations, with excellent results in 52. At least 12 inoculations are necessary. This method has proved valuable. Fifty-two of the 68 cases so treated had no subsequent attacks over a considerable period. The mechanism of the beneficial effects is not explained.

The use of calcium compounds in the treatment of various dermatoses has always been a subject of controversy. Despite unfavorable laboratory data regarding the blood calcium level it has always been my impression that some compounds are helpful. Klostermann[70] did new experimental investigations

of the possibility of efficacious calcium treatment by mouth, using a pure calcium compound without vitamin, a calcium compound with vitamins D_2 and C and a calcium combination preparation with rutin and vitamin C. The blood potassium and calcium levels on the day of administration showed no influence of calcium preparation without vitamin, a decrease from the calcium compound with vitamins D_2 and C and a mild increase from the combination of calcium, rutin and vitamin C. The changes noted after administration of combination preparations are regarded as an effect of vitamin D_2 and rutin, respectively. Vitamin D_2 initially caused a decrease in the blood calcium level, followed by hypercalcemia only after prolonged administration. Rutin increases the blood calcium level. The favorable clinical effect of a combination of rutin and calcium on acute dermatitis was confirmed by these experiments.

Creams containing silicones were introduced for the purpose of protecting the skin against irritants and sensitizers. They have no curative power. However, some physicians persist in using them for therapy. As protective creams and lotions, they have definite value.

Suskind[71] recently reported an industrial and laboratory evaluation of a silicone protective cream. He recorded his observations on the stability or repellent characteristics of films of the formulation when immersed in the major contactants of one plant and in other common industrial contactants. The formulation under study appears to have considerable protective value clinically against light petroleum oils and irritants, such as rust preventives dissolved in such mediums, and against insoluble cutting oils, soluble coolants, aqueous solutions of sulfuric acid and metallic dusts. In vitro films of the formulation appeared to be relatively stable when immersed in aqueous solutions of soap, ethyl alcohol, several commonly used irritants such as salts, slaked lime, ammonium hydroxide, formalin and sulfuric acid. In vitro the cream appeared to be relatively unaffected by cutting oils, soluble coolants, light petroleum oils, water and ethylene glycol. Relative protection was observed clinically against petroleum fractions of low boiling point, such as Stoddard solvent and petroleum spirit, when the cutaneous exposure was intermittent and when the solvent contained a small amount of light petroleum oil. No clinical protection was observed with frequently repeated cutaneous contact with gasoline, naphtha, Stoddard solvent, petroleum spirits and lacquer thinner. No clinical protection was observed against the irritant effects of immersion in a sodium silicate solution. It is suggested that information obtained from systematic studies of protective creams or their equivalents be made available to the physician by means of published reports, to guide him in the choice of such protective measures in the control of occupational skin diseases.

Pruritus vulvae is distressing to patients and often a worry to the physician. It can be caused by many factors — local irritants or sensitizers, local disease, parasites, bacteria or fungi, drugs (it is fairly common after therapy with antibiotics), gastrointestinal disorders and systemic disturbances or diseases. Thorough history taking and examination usually reveal the etiology.

Kleine[72] reports interesting observations of so-called essential pruritus vulvae. Within the first five years of World War II the incidence of essential pruritus vulvae showed a marked increase. The incidence has decreased since 1950, but is at present on the increase again. The women had no diabetes, and no other explanation for the pruritus was found; 80 per cent were over forty-five years of age, and many had hypertension. Pruritus often followed emotional upsets. The social environment was of no importance. The first 103 patients were treated by intravenous injection of vitamin B_1; 90 per cent had a surprisingly rapid cure. Only since 1950 has it been regular practice to determine blood sugar levels, Staub–Traugott curves and pyruvic acid values in these cases. Twenty of 50 patients had latent diabetes; 21 showed an increased blood pyruvic acid level, which is also suggestive of a disturbance in the carbohydrate metabolism; the remaining 9 showed hypersecretion of the cervical glands. In the cases of increased blood pyruvic acid level, both insulin and vitamin B_1 were effective (100 mg. per injection, and the pruritus invariably disappeared after five injections), followed, if necessary, by a course of vitamin B complex. The favorable effect may be attributed to the fact that the pyruvic acid level decreased because the vitamin B_1 enhanced the effect of insulin.

With a diet low in vitamin B_1 insulin has no optimal effect. Vitamin B_1, therefore, also has a favorable effect on latent diabetes. During the postwar period of malnutrition the population depended mainly on carbohydrates, which resulted in relative vitamin B_1 deficiency. The recent rise in the incidence of pruritus may be attributable to the increased consumption of sweets. The question of the frequent concomitance of latent diabetes, pruritus vulvae and hypertension is discussed; this is attributed to disturbances in the centers of the central nervous system, which would also explain the hypersecretion of the glands of the cervix. Various arguments are presented in favor of the existence of an "itching center" in the brain. In cases of hypersecretion of the cervical glands the blood pyruvic acid values were high within the normal limits; it is possible that emotional upsets, via the central nervous system (diencephalon), lead to a disturbance in the sugar metabolism as well as to hypersecretion of the cervix. The fact that it is especially the vulva that

is affected in women subject to disturbances in the sugar metabolism and not the entire body (as in men) is attributed to irritation of the mucosa by acid urine passing the vulva. A change in the reaction of the substances in touch with the skin and the mucosa (whether this is alkaline or acid) may cause irritation.[72]

Conclusion

The development of improved therapy for cutaneous diseases has reduced to a minimum the number of skin diseases referable to a specialist. Syphilis, the other venereal diseases and pyodermas respond rapidly to properly selected antibiotics. Urticaria, pemphigus and acute lupus erythematosus are fairly well controlled by the steroids systemically. Persistent pruritic areas, including the anus and vulva, are often relieved by local steroid therapy. Most cases of chronic lupus erythematosus fade with the use of chloroquine. Skin tuberculosis of many years' duration heals with the new drugs. Cutaneous eruption due to diet disappear rapidly with vitamins. Contact dermatitis, an injury to the skin by an irritant or sensitizer, responds readily if the contactant is removed and a protective dressing is applied to the inflamed skin.

Failure to recognize the etiology should be no deterrent to the successful management of a cutaneous eruption. Despite the apparent numerous illogical methods of treating psoriasis, many clinicians — or nature with their assistance — produce apparent clinical cures or satisfactory temporary relief. Careful observation of the eruption and the patient should suggest the most suitable therapy. Most eruptions can be properly diagnosed.

The need today is increased teaching facilities in dermatology for the proper instruction of medical students, and increased funds for continued dermatologic research. Patients with cutaneous diseases suffer more discomfort and disability than any other group of invalids. They are unwanted at home and at hospitals. Perhaps widespread propaganda and a national drive for funds for the relief of these unfortunates is the answer.

References

32. Kesten, B. M., and Slatkin, M. Diseases related to light sensitivity. *Arch. Dermat. & Syph.* 67:284-301, 1953.
33. Harber, L. C. Clinical evaluation of quantitative differences in ultraviolet absorption of compounds containing the substituted benzoic acid nucleus. *J. Invest. Dermat.* 23:427-435, 1954.
34. Knox, J. M., Lamb, J. H., Shelmire, B., and Morgan, R. J. Light sensitive eruptions treated with atabrine and chloroquine. *J. Invest. Dermat.* 22:11-16, 1954.
35. Cahn, M. M., Levy, E. J., and Shaffer, B. Preliminary and short report: use of chloroquine diphosphate (Aralen) and quinacrine (Atabrine) hydrochloride in prevention of polymorphous light eruptions. *J. Invest. Dermat.* 22:93-96, 1954.
36. Strong, R. A., Sloan, L. H., McQuarrie, I., and Wintrobe, M. M. Chloroquine in salt. *Internat. M. Digest* 9b:58-60, 1955.
37. Fillsbury, D. M., and Jacobson, C. Treatment of chronic discoid lupus erythematosus with chloroquine (aralen). *J.A.M.A.* 154: 1330-1335, 1954.
38. Harvey, G., and Cochrane, T. Treatment of lupus erythematosus with chloroquine sulphate. *J. Invest. Dermat.* 22:89-91, 1954.
39. Tye, M. J., Schiff, B. L., Collins, S. F., Baler, G. R., and Appel, B. Chronic discoid lupus erythematosus: treatment with Daraprim and chloroquine diphosphate (Aralen). *New Eng. J. Med.* 251:52-55, 1954.
40. Ayres, S., III, and Ayres, S., Jr. Chloroquine in treatment of lichen planus and other dermatoses. *J.A.M.A.* 157:136-138, 1955.
41. Rogers, J., and Finn, O. A. Synthetic antimalarial drugs in chronic discoid lupus erythematosus and light eruptions. *Arch. Dermat. & Syph.* 70:61-66, 1954.
42. Fonsari, M. Treatment of pemphigus foliaceus. (Abstract.) *J.A. M.A.* 157:72, 1955.
43. Farber, E. M., and Driver, I. E. Atabrine and chloroquine in treatment of chronic discoid lupus erythematosus: preliminary report. *Internat. M. Bull.* 11:157, 1953.
44. Ungerman, A. H., and Ungerman, M. S. Toxic encephalopathy occurring during topical treatment for tinea capitis. *J. Oklahoma M. A.* 48:304-307, 1955.
45. Thompson, R. C. Ringworm of hands due to Trichophyton rubrum: diagnosis and treatment. *South. M. J.* 47:130-133, 1954.
46. Wooldridge, W. E. Clinical assay of new fungicide, P-594 (2-nitro-2-bromo-1-methoxy-1-phenylpropane). *J. Invest. Dermat.* 21:121-123, 1953.
47. Rothman, S. Systemic disturbances in recalcitrant Trichophyton rubrum (purpureum) infections. *Arch. Dermat. & Syph.* 67:239-246, 1953.
48. Kesten, B. M., Benham, R., and Silva, M. Treatment of onychomycosis due to Trichophyton rubrum. *Arch. Dermat.* 71:52-55, 1955.
49. Rozenthal, M. W., Daeschner, C. W., and Fahlberg, W. J. Clinical evaluation of di-paralene in management of tinea capitis. *J. Invest. Dermat.* 23:119-121, 1954.
50. Casper, W. A., and Malone, J. Occurrence and control of ringworm of scalp in United States. *N. York State J. M.* 54:1645-1651, 1954.
51. Downing, J. G., and Folan, D. W., Jr. Unusual case of cutaneous blastomycosis. *New Eng. J. Med.* 252:103, 1955.
52. Sutliff, W. D., Kyle, J. W., and Hobson, J. L. North American blastomycosis: clinical forms of disease and treatment with stilbamidine and 2-hydroxy-stilbamidine. *Ann. Int. Med.* 41:89-107, 1954.
53. Holsinger, R. E., and Dalton, J. E. Isoniazid therapy in cutaneous tuberculosis and sarcoidosis. *J.A.M.A.* 154:475-481, 1954.
54. Pinkerton, H. Streptomycin and isoniazid in treatment of erythema induratum (Bazin's disease). *Arch. Dermat. & Syph.* 70:511, 1954.
55. Appel, B., Baler, G. R., and Dougherty, E. F. Isoniazid in treatment of chronic lupus erythematosus. *Arch. Dermat. & Syph.* 68: 417-420, 1953.
56. Cormia, F. F., et al. Isoniazid (aydrazid) in treatment of cutaneous diseases: cutaneous tuberculosis, leprosy, sarcoidosis and miscellaneous dematoses. *Arch. Dermat. & Syph.* 64:536-544, 1953.
57. Reiss, F. Glucuronic acid in therapy of psoriasis. *Arch. Dermat. & Syph.* 69:619, 1954.
58. Ingels, A. E. Entosyme in treatment of psoriasis. *California Med.* 79:437, 1953.
59. Rein, C. R., and Goodman, J. J. Efficacy of reserpine (serpasil) in dermatological therapy. *Arch. Dermat. & Syph.* 70:713-717, 1954.
60. Tilley, R. F., and Barry, H., Jr. Chlorpromazine treatment for relief of itching in severe refractory neurodermatitis. *New Eng. J. Med.* 252:229, 1955.
61. Smith, K. A., Fiedler, H. T., and Yhost, C. R. Thorazine. *Am. J. Psychiat.* 111:620, 1955.
62. Ayres, S., III, and Ayres, S., Jr. Selenium sulfide ointment in treatment of seborrheic dermatitis of glabrous skin. *Arch. Dermat. & Syph.* 69:315, 1954.
63. Tronstein, A. J. Evaluation of topical dichloroxyquinaldine (steroxan) as therapeutic agent in dermatology. *J. Invest. Dermat.* 13: 119-123, 1949.
64. Lubowe, I. I. Hexylcaine in management of pruritic dermatoses: clinical evaluation of new local anesthetic. *Arch. Dermat. & Syph.* 69:482-485, 1954.
65. Duemling, W. W. Sodium sulfacetamide in topical therapy. *Arch. Dermat. & Syph.* 69:75-82, 1954.
66. Parish, F. C. Diphenmethanil (prantal) methylsulfate: new approach in treatment of poison ivy dermatitis. *Ann. Allergy* 11:580-582, 1953.
67. Grimson, K. S., Lyons, C. K., Watkins, W. T., and Callaway, J. L. Successful treatment of hyperhidrosis using banthine. *J.A.M.A.* 143:1331, 1950.
68. Levine, I. M., and Harris, O. J. Chemical sympathectomy: new approach to treatment of localized hyperhidrosis. *Arch. Dermat. & Syph.* 71:226-230, 1955.
69. Schiff, B. L., and Kern, A. B. Multiple smallpox vaccinations in treatment of recurrent herpes simplex. *Postgrad. Med.* 15:32-36, 1954.
70. Klostermann, G. F. Untersuchungen zur Rutin-Calcium-Vitamin D$_2$-Behandlung in der Dermatologie. Zugleich ergänzende Bemerkungen zur Arbeit E. Stapel "Klinische Erfahrung mit der Rutin-Calcium-Behandlung in der Dermatologie." *Hautarzt* 3:355-358, 1952.
71. Suskind, R. R. Industrial and laboratory evaluation of silicone protective cream. *Arch. Indust. Hyg.* 9:101-112, 1954.
72. Kleine, H. O. Neue Wege in der Behandlung des Sogenannten essentiellen Pruritus vulvae: Therapie mit Insulin und Vitamin B$_1$. *Zentralbl. f. Gynäk.* 76:220-230, 1954.

MEDICAL INTELLIGENCE

PHEOCHROMOCYTOMA IN PREGNANCY

Cesarean Section and Adrenalectomy

JOHN M. MALONEY, M.D.*

SPRINGFIELD, MASSACHUSETTS

THE coincidence of pheochromocytoma in pregnancy presents a problem. After the diagnosis is made, several alternatives are available. It is only through reports of these cases that the best treatment can be determined. Several recent comprehensive reviews of pheochromocytoma are available.[1-3]

CASE REPORT

The past medical history and the family history of Mrs. E.J.C. seemed noncontributory, although she had infectious hepatitis (?) as a child and, at the age of 12, had been told that she had a heart murmur. No signs or symptoms of heart disease were ever otherwise present. In 1951, at the age of 21, in the last trimester of her 1st pregnancy, she began having "nervous spells," which were described as a sensation of first being warm all over for a couple of hours and then weak and sweaty, with a pounding heart and epigastric distress for several hours. Sometimes, vomiting occurred. Labor and delivery were uneventful, and after delivery the seizures ceased. In the fall of 1953 dilatation and curettage were done for menorrhagia. She became pregnant for the 2d time in January, 1954 (the last menstrual period having begun on January 11 and the estimated date of confinement being October 18). There was a recurrence of "nervous spells" in August, and on the evening of September 3, she was admitted to the Mercy Hospital because of extreme weakness and apprehension.

The pulse was 144, but remained about 100 from then on. The blood pressure was 90/60 in both arms. She was considered to be having episodes of "paroxysmal tachycardia." X-ray study showed a slight increase in the transverse diameter of the heart (14.2 cm., instead of the expected 12.2 cm.). An electrocardiogram on September 6 revealed a sinus tachycardia, with a rate of 114, and peaked P waves in Leads 1, 2 and aVF. The patient was afebrile, and other laboratory studies were negative. She was discharged on September 7.

An aura presented itself around 9 p.m. in the evening of September 19, and symptoms developed 2 hours later. The family became alarmed at 3 a.m., and the patient was first observed in an episode, by a physician. Hospitalization was ordered immediately. The blood pressure was 200/100, the pulse 80, and the temperature 102°F. Several minutes later the pulse averaged 140, varying from 56 (barely perceptible in an artery for a short time) to 150. The blood pressure was at times unavailable and at others 200/100. The possibility of pheochromocytoma was considered at this time. Regitine (phentolamine) 5 mg., was given intramuscularly at 9 a.m., with the return of the pulse and blood pressure to normal. The patient stated, "The attack is over." An electrocardiogram while the arrhythmia was present showed multifocal ventricular extrasystoles, runs of nodal tachycardia with a wandering pacemaker, occasional sinoatrial block, and inverted T waves in Leads 3 and V, to V_5. Urine secreted during an attack gave a ++++ test for albumin, although repeated urinalyses between attacks were normal. The blood sugar during an attack, on an empty stomach, was 140 mg., the nonprotein nitrogen 23.2 mg., and the uric acid 2.4 mg. per 100 cc. Other fasting blood sugars were normal.

On the 2d hospital day the blood pressure was 88/60 and 74/48; the pulse was 88 to 120, and the temperature was normal. The patient was comfortable. X-ray examination suggested a placenta praevia, and a cesarean section was considered (later, at operation, the placenta was found to be in normal position).

On September 24 the patient felt another episode beginning, and phentolamine was given repeatedly. Although the subjective symptoms continued, the blood pressure was under 142/78, and the pulse 100 to 148 and very irregular. By now the diagnosis of pheochromocytoma was definite, and the decision of management was deferred while several medical centers were consulted. Practical suggestions about management were given, but the consultants had had no experience with this neoplasm during pregnancy. Another attack occurred on September 28, with heart sounds very weak (at a rate of 50 to 60) and the blood pressure unobtainable. Throughout this period the patient was alert and amazingly active, with a warm, dry skin.

Cesarean section was scheduled for September 30. On the morning of surgery another episode occurred. Parenteral administration of phentolamine, morphine sulfate and phenobarbital sodium was tried. Signs of fetal distress developed, and a low transverse cervical hysterotomy was performed after a thiopental (Pentothal Sodium) induction. Nitrous oxide, oxygen and ether were administered through an endotracheal tube. Glucose (5 per cent), whole blood and phentolamine were given intravenously.

The effect of the phentolamine was extremely transitory. The pulse was 150 to 50, and the blood pressure 250/150 to 100/70, both varying from instant to instant. After the removal of the baby, the blood pressure was stable at 150/80 with phentolamine. While the abdomen was open the retroperitoneal area and both adrenal glands were palpated, and the tumor was located in the left adrenal gland.

The infant was extremely depressed and required repeated suctioning and stimulation. Death was expected momentarily for the 1st 20 hours. However, the child was normal thereafter.

After delivery the mother did well. The blood pressure, the pulse and an intravenous pyelogram were normal. On October 7 the adrenalectomy was performed. Cortisone, 100 mg. intramuscularly twice daily was given for 2 days preoperatively, and nor-epinephrine (intravenously) and epinephrine in oil (intramuscularly) after adrenalectomy. The anesthesia was the same as that in the cesarean section. Epinephrine in oil (every 12 hours) was continued for 72 hours, and nor-epinephrine was discontinued 12 hours after operation but kept at the bedside for 72 hours in the event of delayed shock.

Grosaly, the left adrenal gland was ovoid and capsulated, measuring 6 by 5 by 3.8 cm. After fixation with potassium bichromate the tumor turned brownish. Microscopically, it was quite characteristic of pheochromocytoma.

The patient went into a state of depression several weeks after operation and responded to reserpine. The blood pressure and pulse remained normal and constant.

DISCUSSION

Pheochromocytoma, judging from the series of cases that are now reported, is not too uncommon. A number of authors describe women who had pregnancies while having symptoms.[4-6] Pheochromocytoma is a curable cause of death that manifests itself as a result of hormonal secretions and not because of its size or position. It is often discovered as an incidental finding at autopsy. These tumors are usually benign, although they can be malignant.

*Member of staff, Mercy, Wesson Memorial and Springfield Municipal hospitals and Holyoke Soldiers' Home and Hospital.

Patients have signs of hypermetabolism, and these cases can be confused with hyperthyroidism, with or without derangement of the glucose metabolism. The first warning of this disorder can be a sudden collapse or death after minor trauma, the induction of anesthesia or surgery. Subjective symptoms are frequently mistaken for psychoneurosis. In pregnancy the secreting medullary tumor can be mistaken for preeclampsia, eclampsia or atypical toxemia. As a cause of collapse at the time of delivery this tumor may be mistaken for an internal hemorrhage, rupture of the uterus or an embolus. The attacks can be spontaneous or caused by movement, exertion, massage of the tumor (which can be lethal), and emotional disturbances. In the case reported above one wonders if the pressure from the fetus, in the last trimester, was related to the attacks.

Formerly, the diagnosis depended on the use of drugs to precipitate an attack or of an antagonist in a person with a persistently discharging tumor. The administration of these drugs was considered in this patient, but it was decided that it was unnecessary, for the course was pathognomonic for a pheochromocytoma and dangerous to the fetus. It is possible now to prove the presence of a secreting medullary tumor by urinary assays that show the amounts of pressor amines in the urine.[7-9]

Sayer, Moses and Mattingly[3] report 2 cases with arrhythmias and diffuse changes in the ST segment and T wave. This study and other articles in the literature emphasize the fact that certain electrocardiographic abnormalities may indicate a pheochromocytoma. This patient had multifocal ventricular extrasystoles, runs of nodal tachycardia with a wandering pacemaker, occasional sinoatrial block, diffuse T-wave changes and peaked P-wave changes.

After the diagnosis it was decided that a cesarean section would be less hazardous than natural labor. There was less chance of mechanical stimulation of the tumor, and while the peritoneal cavity was open the surgeon could explore. A combined surgical and obstetric procedure received scant consideration, and an adrenalectomy in a woman at term seemed only slightly more desirable. The pheochromocytoma may be multiple or ectopic, and exploration of both suprarenal areas and the retroperitoneal space would be difficult in the presence of a large, gravid uterus. Any doubt whether to proceed with the section was dispelled by the x-ray finding of a possible placenta praevia. It was decided to do the section first and then the adrenalectomy as soon as the postoperative condition permitted. The surgeon was to assist with the section for the purpose of exploration.

In the asymptomatic intervals between the time of diagnosis and surgery, blocking agents were withheld because of the possibility of a sudden massive hemorrhage from the placenta praevia. Fear of losing the child made intervention during an attack mandatory.

The next problem was that at the time of evacuation of the uterus severe changes take place in the vascular dynamics, and there can be a massive loss of blood. Therefore, phentolamine, which had an evanescent effect, was discontinued as the time of delivery approached. After the uterus had been emptied and there was no evidence of collapse phentolamine was given intravenously, and the pulse and blood pressure (level of 150 systolic, 80 diastolic) were maintained without difficulty. After operation and throughout the adrenalectomy the course was uneventful.

In 1953 Hunt and McConahey[4] presented 9 cases in which pregnancies coexisted with pheochromocytoma. In 1951 Richards and Hatch[6] reported a series of cases with 2 pregnancies, and Sayer, Moses and Mattingly[5] described 4 pregnancies. To date, 11 cases have been reported, with maternal death in 3, in which 16 pregnancies terminated with 6 fetal deaths. It is believed that the case reported above is the first in which the diagnosis was made ante partum.

Summary and Conclusions

The case of a pregnant woman with a diagnosis of pheochromocytoma that was treated by a cesarean section with later adrenalectomy is reported. Both mother and child are living and well.

Alternative methods of diagnosis and treatment of pheochromocytoma are reviewed.

Cases of this kind should be reported so that sufficient data can be accumulated to determine the advantages of types of treatment.

I am indebted to Dr. Thomas McCarthy, obstetrician, who performed the cesarean section, to Dr. Robert Kelly, urologist, who did the adrenalectomy, and to Dr. Joseph Rini, pathologist at the Mercy Hospital.

References

1. American Medical Association, Council on Pharmacy and Chemistry. *Glandular Physiology and Therapy*. Fifth edition. 611 pp. Philadelphia: Lippincott, 1954.
2. Aranow, H., Jr. Differential diagnosis of pheochromocytoma. *M. Clin. North America* 34:757-761, 1950.
3. Smithwick, R. H., Greer, W. E. R., Robertson, C. W., and Wilkins, R. W. Pheochromocytoma: discussion of symptoms, signs and procedures of diagnostic value. *New Eng. J. Med.* 242:252-257, 1950.
4. Hunt, A. B., and McConahey, W. M. Pregnancy associated with diseases of adrenal glands. *Am. J. Obst. & Gynec.* 66:970-987, 1953.
5. Sayer, W. J., Moser, M. M., and Mattingly, T. W. Pheochromocytoma and abnormal electrocardiogram. *Am. Heart J.* 48:42-53, 1954.
6. Richards, V., and Hatch, F. N. Surgical experiences with pheochromocytoma. *Ann. Surg.* 134:60-54, 1951.
7. von Euler, U. S. Increased urinary excretion of noradrenaline and adrenaline in cases of pheochromocytoma. *Ann. Surg.* 134:929-933, 1951.
8. *Year Book of Endocrinology (1953-1954 Year Book Series)*. Edited by G. S. Gordan. 390 pp. Chicago: Year Book Publishers, 1954.
9. Goldenberg, M. Adrenal medullary function. *Am. J. Med.* 10: 627-641, 1951.

THE COAL MINER AND HIS DOCTOR

JOHN PEMBERTON, M.D.*

BOSTON

"THE present practices of medicine in the coal fields on a contract basis cannot be supported. They are synonymous with many abuses and they are undesirable and in many instances deplorable."

These blunt statements appeared in the report, published in 1947, of a medical survey of the bituminous-coal industry instigated by the federal Government and conducted by a commission headed by Rear Admiral Joel T. Boone.[1] The survey was one of the results of the 1946 coal strike. Another was the creation of the United Mine Workers of America Welfare and Retirement Fund for bituminous-coal miners and their dependents, financed by a 5-cent royalty per ton of coal mined. The royalty has now been increased to 40 cents per ton and yields an annual income of $132,000,000. The two largest items of expenditure are retirement pensions and the medical services. The Fund is administered by 3 trustees, of whom 1 is nominated by the coal operators, 1 by the United Mine Workers and 1 by the other 2 in agreement. The Boone report revealed in unambiguous terms the substandard state of the medical services existing in many parts of the soft-coal area. By means of the Welfare and Retirement Fund attempts are now being made to improve these services.

For more than half a century the coal miner depended for his medical care on the services of the "check-off" doctor. This doctor was normally hired by the mine operator and remunerated by sums deducted from the miner's wage, amounting in recent times to about $3 a month. He also undertook compensation work for the company. This system was often disliked by the miner, and in at least 1 case it led to an actual strike, which occurred after the posting of the following notice in a West Virginian mine early in the century:

> "Each and every married man will be charged $1.00 per month for medical services and each and every single man fifty cents per month . . . There will be no exceptions to this clause and you need not therefore ask, for if you cannot comply with the rules of our company you need not apply for work . . . No other physician will be recognized as attending company employees and no collections will be made for any other physician."[2]

Although this method of appointing physicians was often unpopular it should be pointed out that the mine operators often provided the only medical service available to the mining camps, and even to this day the "check-off" system, though no longer compulsory except in a few cases, is the commonest way in which the coal miner elects to obtain his prepaid medical care.

In underdoctored areas like the southern part of West Virginia and parts of Kentucky and Tennessee there has been a tendency for the "check-off" doctor to undertake the care of more patients than he could properly look after and to carry out procedures such as complicated surgical operations for which he had received insufficient training. This state of affairs was apparently in the minds of the members of the Committee on Medical Care for Industrial Workers of the American Medical Association[3] when they drew up their recommendations after carrying out a survey of local medical and hospital facilities in the mine areas of the states mentioned above in 1952:

> General practitioner services should be greatly expanded and strengthened in these areas . . . [and] The further development of community type hospitals based on recognized standards, and open to all qualified physicians including general practitioners should be strongly encouraged and supported by the state medical societies and by the AMA and the AHA.

During a recent medical survey of coal miners in the bituminous area I had an opportunity of observing some of the methods now being employed by the trustees of the Welfare and Retirement Fund and their medical administrators to improve the medical services available to the coal miner.

In general the Fund has concentrated on providing free specialist and hospital care and rehabilitation for the coal miner and his dependents and has only indirectly affected general practice by making specialist consultation and hospital facilities more easily obtainable by paying for these. In a few cases, however, clinics have been instigated by the Fund, with general practitioners, who may be the local "check-off" doctors, practicing in close contact with visiting or full-time specialists.

At one clinic in a mining town some 15 miles from Pittsburgh there were 3 such general practitioners and 17 part-time consultants. The general practitioners are remunerated by means of the company "check-off" whereas the consultants, who nearly all have appointments at the University of Pittsburgh Medical Center, are paid by the Fund on a retainer-salary basis. The general practitioners have admitting privileges at the local hospital. The consultants can also admit patients to the local hospital or, in cases requiring complicated diagnostic or therapeutic technics, to one of the Pittsburgh hospitals. All consultant and hospital charges for miners and their dependents are paid for by the Fund. The services of the center, however, are also available on a fee-paying basis to nonminers living in the community. The clinic contains, in addition to the usual consultation rooms and offices, a clinical laboratory and an x-ray department. Patients are also seen in an office in a nearby suburb by one of the general practitioners

*Senior lecturer in social and industrial medicine, University of Sheffield, England; consultant in social and industrial medicine, United Sheffield Hospitals; Rockefeller Traveling Fellow in Medicine, Harvard School of Public Health.

and can be referred to the center for consultant advice when necessary. Thus, a remarkably complete medical service is made available to the scattered populations of this group of small mining towns. By providing good office-consultant services hospital admissions have been decreased by half. Another clinic in Ohio, too far from Pittsburgh to depend for its consultant staff on visiting specialists from the University Medical Center, employs mainly full-time salaried specialists. There are good laboratory and x-ray facilities in the center, and all the specialists have admitting privileges at the local hospital. In another town in West Virginia the Fund makes use of a long-established private clinic and hospital combined. In this case it simply pays for services given to its beneficiaries, billed in the usual way.

These clinics are merely three examples of the ways in which the administrators of the United Mine Workers Fund are endeavoring to improve the medical services available to the coal miner and his dependents. The general shortage of good hospital accommodation in the southern part of the bituminous-coal field, which still has to rely largely on the small type of proprietary hospital with closed staffing arrangements for its hospital service, has led the trustees of the fund to finance the building of 10 new hospitals in the states of West Virginia, Tennessee and Kentucky.[4] These hospitals are under construction and are expected to be completed by the end of this year. They will together provide about 900 beds, and it is estimated that a staff of more than 100 consultants will be required. When completed they will be opened to the whole community, and local doctors in good standing will be given admitting privileges.

The medical administrators of the Welfare and Retirement Fund have a difficult task in bringing the medical services available to the coal miner and his dependents up to a high standard. That remarkable progress has been achieved since 1947 is due, in no small measure, to the fact that innovations have been gradual and that the organizers have proceeded in consultation with the appropriate committees of the American Medical Association and the state medical associations. The medical section has also been fortunate in having an exceptionally able medical director in the person of Dr. Warren F. Draper to guide it, and an income of about $50,000,000 a year with which to achieve its objects.

References

1. *A Medical Survey of the Bituminous Coal Industry: Report.* 244 pp. Washington, D. C.: Department of Interior, 1947.
2. Korson, G. *Coal Dust on the Fiddle: Songs and stories of the bituminous industry.* 460 pp. Philadelphia: University of Pennsylvania Press, 1943.
3. Medical-hospital problems in bituminous coal mining areas. American Medical Association, 1953.
4. U.M.W.A. Welfare and Retirement Fund. Report for year ending June 30, 1954.

CASE RECORDS
OF THE
MASSACHUSETTS GENERAL HOSPITAL

Weekly Clinicopathological Exercises

FOUNDED BY RICHARD C. CABOT

BENJAMIN CASTLEMAN, M.D., *Editor*

VIRGINIA W. TOWNE, *Assistant Editor*

CASE 41321

Presentation of Case

First admission. A fifty-one-year-old housewife entered the hospital because of a four-month history of progressive dysphagia and weight loss.

The dysphagia had gradually worsened until she was unable to swallow even fluids. The symptoms had been associated with a 30-pound loss in weight. The past history revealed an episode of enlarged cervical lymph nodes ten years previously, a biopsy of which had been reported as showing lymphoma. She subsequently received an intensive course of x-ray therapy to the neck area and also to the the abdomen, where a mass had likewise allegedly been present. There had been no recurrence of these symptoms in the interim.

Physical examination revealed a well developed woman with two linear scars on the left side of the neck. No superficial lymphadenopathy was detected. The remainder of the examination was negative.

The temperature was 98.6°F., the pulse 88, and the respirations 22. The blood pressure was 125 systolic, 80 diastolic.

X-ray studies disclosed a complete obstruction to the flow of barium at the level of the jugular notch. An esophagoscopy revealed a high obstruction; a biopsy was reported as showing squamous-cell carcinoma, Grade 3. After a gastrostomy an exploration of the cervical esophagus revealed a fixed, inoperable tumor mass extending from 1 cm. below the level of the cricoid cartilage behind the superior aspect of the sternum. After operation the patient received 3000 r of x-ray therapy through an anterior portal and a similar amount through a posterior portal to the cervical esophagus. She was discharged with a gastrostomy feeding tube.

Second admission (five months later). She was readmitted to the hospital because she had not improved, being still unable to swallow saliva. X-ray studies at this time showed a fusiform narrowing of the upper esophagus through which barium passed with difficulty (Fig. 1). Esophagoscopy and bougienage demonstrated a weblike fibrous stricture of the upper esophagus. A biopsy was reported as showing acute and chronic inflammation without evidence of carcinoma.

Third admission (six months later). After esophageal bougienage the patient gradually became able

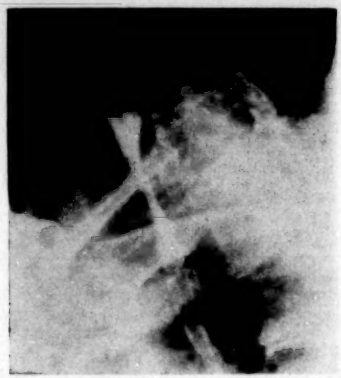

FIGURE 1. *Spot Film of the Esophagus Several Months after Irradiation Was Instituted, at the Time When the Patient Began to Have Secondary Symptoms of Dysphagia, Showing Smooth Esophageal Narrowing in the Thoracic Inlet.*

to take increasing amounts of food, with an associated gain in weight. She was readmitted to the hospital for gastrostomy closure, which was performed without event. A barium-swallow examination, done two months later, showed marked improvement in the caliber of the esophagus (Fig. 2).

Fourth admission (two and a half years later). She was admitted to the hospital because of the onset of blood-streaked stools, nausea and sharp, shooting pains in the right groin and back, which had developed over a four-month period. She had experienced little swallowing difficulty, and had required no bougienage for the previous six months.

She appeared pale and in no acute distress. There was no lymphadenopathy. The liver edge was palpable 3 fingerbreadths below the right costal margin, and the spleen was firm, nontender and enlarged to 2 fingerbreadths below the left costal margin. Rectal examination was negative. There was ++ pitting edema of both legs.

Urinalysis was negative. Examination of the blood revealed a white-cell count of 4500, with 73 per cent neutrophils, 22 per cent lymphocytes, 4 per cent eosinophils and 1 per cent monocytes, and a hemoglobin of 13.0 gm. per 100 cc. The alkaline phosphatase was 5.3 units, the total protein 6.59 gm., with an albumin-globulin ratio of 2.1, and the nonprotein nitrogen 22 mg. per 100 cc.; the prothrombin time was 75 per cent of normal, and cephalin flocculation ++ in twenty-four and +++ in forty-eight hours. Barium-enema examination of the colon disclosed a 2-cm. filling defect in the terminal ileum. A right colectomy with excision of the terminal 9 cm. of ileum was performed. A pathological diagnosis of malignant lymphoma, follicular type, with involvement of the bowel-resection margins and regional lymph nodes, was made. The patient subsequently received irradiation with a total of 1050 r to both an anterior and a posterior abdominal field.

Fifth admission (six months later). After the colectomy she improved and felt moderately well. By now she was able to swallow all foods without difficulty. However, about four months after the last hospitalization, cervical and axillary lymphadenopathy was

FIGURE 2. *Spot Film of the Esophagus Eight Months Later. The proximal portion of the esophagus is shown to be of normal caliber. The dysphagic symptoms had disappeared.*

discovered during a routine follow-up examination. Readmission was advised. The liver and spleen were palpable 3 fingerbreadths below the costal arch. A cervical-lymph-node biopsy revealed malignant lymphoma of the follicle type. After a course of x-ray therapy to the cervical and axillary regions, the adenopathy disappeared. Another barium-swallow examination showed only slight irregularity at the level of the thoracic inlet. An upper gastrointestinal series was normal.

Sixth admission (three years later). She had been in good health until a month previously, when she noted loss of energy, lack of appetite, weight loss,

multiple chest, back and abdominal pains and a diffuse swelling over the left side of the head.

Physical examination revealed a well developed, pale woman in much poorer health than previously. A smooth swelling was present over the right parietal bone, and a 2-cm. nodule in the left posterior scalp. The liver and spleen were palpable 4 fingerbreadths below the costal margin. No abdominal masses were palpable. There was tenderness over the lower thoracic and upper lumbar spine. Pelvic examination was negative.

The temperature was 101°F., the pulse 90, and the respirations 16. The blood pressure was 140 systolic, 80 diastolic.

Examination of the urine was negative. Examination of the blood showed a hemoglobin of 9.4 gm. per 100 cc. Reticulocytes were 0.2 per cent. The white cells were not remarkable. The red cells were normocytic and normochromic, with slight to moderate anisocytosis and poikilocytosis. The platelets appeared increased and showed many bizarre forms. The white-cell count was 4700, with 78 per cent neutrophils, 15 per cent lymphocytes and 6 per cent monocytes. The nonprotein nitrogen was 26 mg., the bilirubin 0.4 mg., the serum calcium 8.4 mg., the phosphorus 4.1 mg., the alkaline phosphatase 3.7 units, the total protein 6.4 gm., the albumin 4.7 gm., and the globulin 1.7 gm. per 100 cc. The serum iron was 40 microgm. (normal, 125 to 200 microgm.), and the serum iron-binding capacity 290 gamma per 100 cc. (14 per cent saturation). A stool gave a negative guaiac test. A bone-marrow smear showed marked depletion of erythroid and myeloid cells by tumor cells resembling immature and mature lymphocytes.

The patient was given whole-blood transfusions, 1200 r to the scalp and a course of nitrogen mustard on three alternate days. Before the mustard therapy the white-cell count was 1900, with 89 per cent neutrophils, 10 per cent small lymphocytes and 1 per cent monocytes. Daily white-cell counts showed slight variation from the pretreatment level, and she was discharged sixteen days after admission.

Final admission (two months later). She was admitted to the hospital complaining of diffuse, generalized pains, anorexia and nausea. In the interim she had had continuous pains in the chest, back, abdomen, groins and legs. She had been taking cortisone part of the time, which had been replaced by Meticorten. Additional therapy included Butazolidin.

Physical examination was unchanged from the previous admission except for peripheral edema and exquisite tenderness over the bones of the arms and legs.

The temperature was 99.6°F., the pulse 100, and the respirations 24. The blood pressure was 140 systolic, 80 diastolic.

Urinalysis was negative. Examination of the blood revealed a hemoglobin of 8.2 gm. per 100 cc. and a white-cell count of 3100, with 69 per cent neutrophils, 17 per cent lymphocytes, 4 per cent monocytes, 5 per cent young neutrophils, 3 per cent myelocytes, 1 per cent metamyelocytes and 1 per cent nucleated red cells. The serum iron was 180 microgm. per 100 cc. The alkaline phosphatase was 5 units per 100 cc. A stool gave a negative guaiac test. The gastric aspirate gave a ++++ guaiac test and contained no tumor cells. A barium-meal examination outlined a normal esophagus. The gastric folds were thickened and irregular, but the walls were soft and flexible. Two small ulcerations were noted on the lesser curvature in the antrum near the pylorus.

The patient was treated with whole-blood transfusions. One thousand r was given to the stomach. She showed slight improvement, with less epigastric pain and less pain over the bones. Daily white-cell counts hovered between 2000 and 800 cells, the latter on three consecutive counts during the last five days of life, with a differential of 74 per cent neutrophils, 6 per cent lymphocytes, 4 per cent monocytes, 12 per cent band forms and 4 per cent metamyelocytes. On the seventeenth hospital day she complained of numbness of the lower face and jaws. Chlorpromazine was started, and Butazolidin discontinued, to be started again several days later. She had been afebrile during the hospital admission until three days before death, when the temperature rose to 101°F., with elevations to 103°F. Increasing weakness and pain on swallowing developed. The pharynx was injected, but no ulcerations were noted. She lapsed into coma on the thirtieth hospital day, and died the next morning.

Differential Diagnosis

Dr. Moses M. Suzman*: I wonder if I may see the x-ray films of the esophagus.

Dr. Joseph Hanelin: Many films were made over the years. Those from the initial examination are missing. In the film made a few months after radiation had been given, when the patient was again having dysphagia, there is a short segment of narrowing at the level of the thoracic inlet approximately 4 cm. in length. Subsequently, with bougienage, that area has ballooned out, is of about normal caliber and is only slightly stiffer than normal. The appearance of the esophagus remained good throughout the remainder of her life. We never saw evidence of local recurrence, nor did she have any swallowing difficulty after bougienage was started.

Dr. Suzman: Was the original obstruction complete?

Dr. Hanelin: The description was that of a complete obstruction.

*Visiting physician, *pro tempore*, Massachusetts General Hospital; senior physician, Johannesburg General Hospital, Johannesburg, South Africa; lecturer in medicine, Witwatersrand University Medical School, Johannesburg.

DR. SUZMAN: Do we know whether the contours were smooth?

DR. HANELIN: It was described as a complete obstruction.

DR. RICHARD H. SWEET: It must have been quite complete; otherwise, we should not have done a gastrostomy before starting treatment. My recollection is that it was quite a tight obstruction.

DR. AUSTIN L. VICKERY: I do not think that there is much question that she was unable to swallow even her own saliva.

DR. SUZMAN: At the age of forty-one years, the patient was found to be suffering from lymphoma involving the cervical and also probably the abdominal lymph nodes, for which she received deep x-ray irradiation. That this diagnosis was very probably correct is supported by the subsequent history, which revealed about fourteen years later the presence of malignant follicular lymphoma of the terminal ileum, with involvement of the regional lymph nodes and later of the cervical and axillary lymph nodes. After surgery and x-ray therapy she apparently remained fairly well until three years later, when she began to have focal and constitutional symptoms, which could be attributed to a more diffuse recrudescence of the lymphoma process involving also the skeleton. She had fever and had become anemic and leukopenic. A bone-marrow aspiration showed marked depletion of the red-cell and white-cell series and invasion by tumor cells resembling immature and mature lymphocytes, again confirming the lymphomalike nature of the disease. With blood transfusions and nitrogen mustard therapy some benefit must have accrued, since she was discharged from the hospital after about two weeks. However, the improvement was short-lived, for she was readmitted three months later with generalized pain, anorexia and nausea, despite having received cortisone, Meticorten and Butazolidin. She was still anemic, and the peripheral blood now contained immature red and white blood cells and showed a progressive diminution in the total leukocyte count, a feature suggestive of myelophthisic anemia, although the possibility that Butazolidin intoxication was involved needs serious consideration. The severe generalized and skeletal pains were consistent with a diffuse infiltrative process involving the bones. The abdominal pain, the presence of blood in the gastric aspirate, the thickening and irregularity of the gastric folds and the peptic ulceration in the pyloric antrum were apparently considered evidence of lymphomatous infiltration, because 1000 r of deep x-ray irradiation was subsequently delivered to the stomach. However, to my mind, these manifestations may have resulted from the combined administration of three therapeutic agents, each of which in its own right is reputed to damage the stomach wall—namely, the cortisone, the Meticorten and, particularly, the Butazolidin.

During the last three days of life, high fever, a painful, injected throat and increasing coma were reported, features reminiscent of uncontrolled malignant leukopenia. Antibiotic therapy, if administered, was not mentioned.

DR. BERNARD M. JACOBSON: It was not given.

DR. SUZMAN: It appears that this patient was suffering from follicular lymphoma of seventeen years' duration, during the last four years of which a more malignant change had taken place, with diffuse dissemination to the liver, spleen, alimentary tract, skeleton and possibly the skull and with terminal myelophthisic anemia and leukopenia. Terminal infection, probably involving the lungs, may have played a part in the final outcome, particularly in producing the extreme pyrexia in the last three days. The long duration of the follicle type of lymphoma is not unusual; of all the subtypes of lymphoma, this is generally considered to be the least malignant and to have a protracted course.

I have not yet mentioned the interlude of difficulty in swallowing that began ten years after the onset of the illness, when a tumor mass involving and completely obliterating the upper end of the gullet was discovered. Although it may have been lymphomatous, it probably was not, and, in any event, this lesion can be excluded as a factor responsible for death. The obstruction seen in a barium-swallow examination and on esophagoscopy was complete, and a biopsy revealed a squamous-cell carcinoma, Grade 3. In my estimation there is little likelihood of confusion in the histologic differentiation of these two lesions. Before irradiation complete obstruction was noted in the barium-swallow examination whereas several months after radiation, without bougienage, some barium passed through the esophagus. If this mass had been lymphomatous one would have expected rapid resolution after even a much smaller dose of irradiation. In the next seven years, up to the time of death, the patient did not experience dysphagia again so that from a practical standpoint she had enjoyed a clinical cure of the alleged esophageal carcinoma.

That a clinical cure is unusual is conceded, but it is by no means unheard of. Carcinoma of the esophagus is generally considered to be highly malignant, with an average duration of life after detection, according to various writers, not exceeding six to nine months, regardless of the mode of treatment employed. It is said that, in comparison with adenocarcinoma, the squamous-cell type is accredited with slower growth and with a later appearance of metastases. This is to be expected since the carcinoma of the upper end of the esophagus resembles in many respects that which involves the postcricoid area, the hypopharynx and the buccal cavity. In these sites carcinoma is known to grow slowly and to exhibit significant responsiveness to deep x-ray irradiation.

In patients with carcinoma of the hypopharynx, Coutard[1] reported a five-year clinical cure in 12 per cent of his cases after deep x-ray irradiation. Ahlbom,[2] of Stockholm, claims an over-all 7 per cent absolute cure with complete healing over a period of five to eight years, but when the radiation dose was maintained at 5000 to 6000 r, the rate of cures was increased to 20 per cent. If this substantial proportion of favorable results can be obtained by irradiation in hypopharyngeal carcinoma it is not inconceivable that a similar effect may be obtained when the growth involves the upper esophagus, particularly since the carcinomas in these two sites are probably of the same type.

Before concluding, I should like to say a few words about the interesting relation of the Plummer–Vinson syndrome (anemia, glossitis and dysphagia) to carcinoma of the upper esophagus, hypopharynx and buccal cavity. This syndrome occurs mainly in middle-aged women, who, it has been pointed out by many observers, show a predisposition to cancer of these sites. Moreover, cancer of the upper esophagus is far more common in women than in men. Ahlbom[3] has reported that 70 to 90 per cent of women with carcinoma of these sites have suffered from the Plummer–Vinson syndrome, either at the time or previously. At the Massachusetts General Hospital, nearly twenty-five years ago, in a series of 8 cases of the Plummer–Vinson syndrome that I had the opportunity of studying,[4] 1 patient, a female aged forty-five years, had a squamous-cell carcinoma of the tongue and anterior fauces. Another, a forty-eight-year-old female, at autopsy, after a fatal bougienage, showed changes in the esophageal mucosa, the epithelium of which was composed of rather large cells appearing somewhat immature and containing large vesicular nuclei and occasional mitotic figures giving an appearance similar to that of leukoplakia and suggestive of a precancerous state. The patient under discussion, being a middle-aged woman with carcinoma of the upper end of the esophagus, might be regarded as the type of case with a reasonable chance of responding to x-ray irradiation given in adequate dosage.

My final diagnoses are lymphoma of the follicle type, which had assumed a more malignant character with widespread dissemination, and squamous-cell carcinoma of the upper esophagus, healed under the influence of deep x-ray irradiation.

Clinical Diagnoses

Squamous-cell carcinoma of esophagus, cured.
Malignant lymphoma, follicle type, with widespread dissemination.

Dr. Moses M. Suzman's Diagnoses

Squamous-cell carcinoma of esophagus, cured.
Malignant lymphoma, follicle type, with widespread dissemination.
Myelophthisic anemia.

Anatomical Diagnoses

Malignant lymphoma, generalized, lymphoblastic type, originating as follicle type eighteen years before.
(Squamous-cell carcinoma of esophagus), eight-year cure, after radiation therapy.
Myelophthisic anemia.
Gastric ulcers, peptic type.

Pathological Discussion

Dr. Vickery: It was gratifying to hear Dr. Suzman place a good deal of confidence in the diagnosis made on the original biopsy of the esophagus. Because of the prolonged course of this patient with inoperable carcinoma, we were less confident about it and took the liberty of reviewing the slides. The original biopsy of the esophagus showed an infiltrating squamous-cell carcinoma without question. Dr. Sweet, you followed this patient for about eight years; would you comment?

Dr. Sweet: I saw her during all this long history except in the beginning, when she was a patient of Dr. Charles G. Mixter, who referred her to me for treatment of the carcinoma of the esophagus. At that time there was no clinical evidence of lymphoma. During the exploration of the neck, which was planned so that a tube of skin could be substituted for the esophagus if the tumor were operable, I saw nothing that looked like lymphomatous nodes, but the local situation made the lesion inoperable. She is one of a few patients whom I have seen who have had an unusually good response to x-ray therapy for carcinoma in the cervical area of the esophagus. I have the impression, at least from my limited experience, that the response is more favorable in that part of the esophagus than elsewhere. I am not sure that that is correct, for if the radiologists could deliver an equivalent dose to a lesion of the squamous type in other portions of the esophagus, they ought to have comparable results. Perhaps there are a few such cases that Dr. Hanelin can tell us about. I know of several such patients who have lived a long time after x-ray therapy. The results of treatment of carcinoma of the esophagus by surgery, however, are by no means as pessimistic as one might infer from Dr. Suzman's comment. In the favorable group, without positive lymph nodes, that we have been following recently, the five-year survival is 34 per cent if the carcinoma lies in the lower end of the esophagus and 14 per cent if it lies at the midesophagus; however, in the cervical area, the results are much less favorable. I have not yet seen any five-year survivals after surgery in this group because there we cannot effect a satis-

factory cancer operation; we cannot combine a wide resection of both sides of the neck with the production of a skin tube to replace the esophagus. I have recently decided that x-ray therapy is preferable to surgery in that site unless there happens to be a very small tumor that we can resect.

I also did the operation on the intestinal tract; that lesion was obviously lymphoma. It had nothing to do with the carcinoma.

DR. VICKERY: Dr. Hanelin, would you comment about the unusual nature, if you consider it such, of this eight-year postirradiation cure of carcinoma of the upper esophagus?

DR. HANELIN: Our experience with treatment of carcinoma of the esophagus is generally dismal. Palliation, however, may frequently be effected although actual cure, as in this case, is a rarity. Carcinomas of the proximal esophagus have a higher rate of irradiation cure than elsewhere because the patients with these lesions probably become symptomatic earlier in the course of the disease, and we are more frequently given the opportunity of treating the lesions earlier because the surgical resection is fraught with much technical difficulty.

DR. VICKERY: Dr. Benedict, you also saw this patient.

DR. EDWARD B. BENEDICT: When I first saw her she had a gastrostomy and could not swallow water or her own saliva. With a hypopharyngoscope I saw only a dimple where the mouth of the esophagus should have been; I could not see any lumen at all. I aimed the smallest bougie, about a No. 10, at this dimple; the bougie passed and went into the distal esophagus without too much difficulty. I increased the size of the bougies gradually, and she was able to swallow water. Later, after the second esophagoscopy, when she was able to take soft food, I had her swallow a thread, and, using the thread as a guide, I passed bougies of gradually increasing sizes. At first this was done every week or so in my office. After about two years I could pass a No. 45, which is the largest size of all. Thereafter, she did not require any more bougienage and apparently was completely relieved. I never thought that the weblike structure was anything more than radiation fibrosis in the upper esophagus.

DR. HANELIN: There have been a number of patients who have favorably responded to bougienage after radiation.

DR. BENEDICT: Yes, but this was the most dramatic response.

DR. JACOBSON: In line with Dr. Suzman's idea of presupposing the Plummer–Vinson syndrome, this patient looked like a woman who might have had that previously: she was large, and had large jawbones, blond hair and blue eyes — the constitutional features that are common in pernicious anemia and in primary hypochromic anemia.

DR. VICKERY: Microscopical study of the bowel, resected four years after the exploration of the cervical esophagus, showed that the entire wall was infiltrated with a lymphoid mass. This presented the follicular pattern characteristic of a malignant lymphoma of the giant-follicle type. A lymph node from the mesentery indicated a diffuse involvement by the same process. A lymph node removed from the neck the next year showed a similar picture. Certainly, this type of lymphoma is known to pursue, not infrequently, a very slow course sometimes extending over many years, and perhaps terminating in a slightly different histologic form with a greater malignant potential, which, indeed, is what apparently occurred in this patient.

At autopsy there was widespread involvement with malignant lymphoma. Most of the bone marrow was pale and largely replaced with lymphoma — the condition that was responsible for the myelophthisic anemia and leukopenia. In addition lymphoma deposits were noted in the spleen, liver, kidneys, ovaries, thyroid gland and lymph nodes. The lymphoma was more characteristic of the lymphoblastic type than of the giant-follicle form, signifying a transition to a more malignant process.

I was interested in Dr. Suzman's remark about the ulcerations in the stomach. There were two large peptic ulcers in the stomach. We could not determine that these were on the basis of any lymphomatous infiltration. I was curious about the relation between the development of these and the antitumor chemotherapy that was given. I am not qualified to speak on that point.

The esophagus was closely examined and was found to be normal except for microscopical evidence of fibrosis in the periesophageal tissue. There was no evidence of residual carcinoma.

DR. JACOBSON: I might add that for about two months before death the patient had dyspeptic symptoms, which I thought were probably due to gastritis or ulcers induced by cortisone and later by Butazolidin. We know that Butazolidin will do even more effectively what cortisone does, and we were fully prepared to have Dr. Hanelin show us these two peptic ulcerations.

DR. VICKERY: We certainly have seen peptic ulcers in the stomachs of patients who have been on extensive cortisone therapy.

DR. HANELIN: Was there any evidence of amyloid disease in the stomach?

DR. VICKERY: No.

DR. HANELIN: Was there any evidence of lymphoma in the stomach at the time of autopsy?

DR. VICKERY: No; that is what I was referring to regarding the ulcers.

DR. HANELIN: Lymphoma was suspected in the upper half of the stomach and not in the area of the ulcerations, which looked benign. I examined the

stomach many times in the past seven years; the folds were distinctly larger in the last examination, which certainly raises the question of lymphoma. The patient may have received enough treatment to take care of the tumor if it was present there.

DR. JACOBSON: About a week before death she complained of numbness on both sides of the face, jaw and tongue. The neurologist and I both believed that this was either a peripheral trigeminal neuritis or possibly bilateral nuclear involvement by tumor, which is rare and difficult to imagine. We also thought it was possible that trigeminal symptoms resulted from the Butazolidin in a way similar to that previously seen from the antimyeloma drug, stilbamidine.

DR. VICKERY: The gross examination of the brain and trigeminal nerves was negative.

DR. SUZMAN: May I make one more comment? The Plummer–Vinson syndrome is considered to be a nutritional-deficiency disease and can be controlled by adequate dietary treatment. Since a high proportion of carcinomas in this region supervene on the Plummer–Vinson syndrome this may indicate a relation between nutritional deficiency and the final development of cancer.

REFERENCES

1. Coutard, H. Cited by Ahlbom.[2]
2. Ahlbom, H. E. Results of radiotherapy of hypopharyngeal cancer at Radiumhemmet, Stockholm, 1930-1939. *Acta radiol.* 22:155-171, 1941.
3. *Idem.* Simple achlorhydric anaemia, Plummer-Vinson syndrome, and carcinoma of mouth, pharynx and oesophagus in women: observations at Radiumhemmet, Stockholm. *Brit. M. J.* 2:331-333, 1936.
4. Suzman, M. M. Syndrome of anemia, glossitis and dysphagia: report of eight cases with special reference to observations at autopsy in one instance. *Arch. Int. Med.* 51:1-21, 1933.

CASE 41322

PRESENTATION OF CASE

First admission. A seventy-eight-year-old man entered the hospital because of increasingly severe dyspnea and a chronic cough.

About a month previously the patient consulted his family physician because of the onset of a cough, which had been gradually growing worse over a week's period. The cough was not preceded by cold symptoms, chills or fever. The physician prescribed expectorants, which did not give much relief. The cough progressed and became productive of small amounts of whitish, nonfoul sputum. There had been no hemoptysis. The coughing spells were worse at night and were associated with a grabbing pain in the left upper part of the chest. He had awakened several nights with profuse sweating. Dyspnea on climbing stairs was also one of the entering complaints. He had lost about 10 pounds in weight during the past month.

Except for an episode of pneumonia ten years previously, for which he was hospitalized, there was no past history of either pulmonary or cardiac symptoms. On admission he insisted that he had been well before the coughing spells. He had emigrated from Finland at the age of thirty and had always been employed in steel construction work, principally as a riveter; he had retired two years previously. Until ten years before, he had smoked two packages of cigarettes daily.

Physical examination showed a thin, well developed, alert man who appeared chronically ill. He

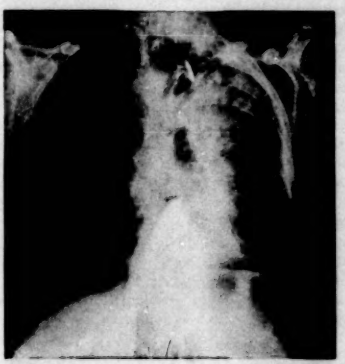

FIGURE 1. *Posteroanterior Roentgenogram of the Chest Taken on Admission, Showing Extensive Consolidation of the Left Upper Lobe.*

was tachypneic and had a hacking productive cough. There was a marked kyphosis. The chest was generally hyperresonant except for dullness over the left upper portion. Bronchial breathing was heard over this area. The heart was enlarged to the left; the rhythm was irregular, with 8 to 10 premature beats per minute. The pulmonic second sound was greater than the aortic. There was a soft Grade 2 apical systolic murmur. The abdomen was soft, with the liver palpable 1 or 2 cm. below the right costal margin, but was otherwise normal. The prostate was enlarged to about one and a half times the normal size. The fingernails showed no true clubbing.

The temperature was 100°F., the pulse 104, and the respirations 36. The blood pressure was 146 systolic, 70 diastolic.

Urinalysis was negative. Examination of the blood revealed a hemoglobin of 12 gm. per 100 cc. and a white-cell count of 12,000, with 57 per cent neutrophils. A stool guaiac examination was negative. The nonprotein nitrogen was 26 mg. per 100 cc.; the prothrombin time was normal. The blood Hinton test was negative. A sputum culture grew out mostly *Escherichia coli.* An x-ray examination of the chest with a barium swallow and fluoroscopy showed a large consolidated area in the left upper lobe, with considerable emphysema of the aerated lung and a displacement of the right lung to the left anteriorly (Fig. 1). Spot films of the lung lesion demonstrated

no definite obstructing lesion in the left upper bronchus. An electrocardiogram disclosed a sinus tachycardia. Bronchoscopy showed a downward displacement of the left-upper-lobe orifice and a distorted but freely movable carina. The findings were those of a severe hemorrhagic bronchitis. Smears of material from the bronchial tree were negative for acid-fast bacilli. A second sputum culture obtained on the third hospital day produced an abundant growth of Friedländer's bacillus.

In the hospital the patient ran a temperature spiking to about 100°F. each day, and the white-cell count rose to 21,000, with 93 per cent neutrophils, on

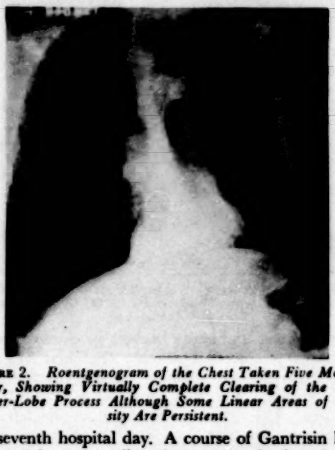

FIGURE 2. *Roentgenogram of the Chest Taken Five Months Later, Showing Virtually Complete Clearing of the Left-Upper-Lobe Process Although Some Linear Areas of Density Are Persistent.*

the seventh hospital day. A course of Gantrisin later followed by tetracycline therapy was instituted, and postural drainage was started. By the twelfth hospital day the cough symptoms had definitely improved, but a chest film showed only slight improvement. He was finally discharged on the eighteenth hospital day to be maintained on a course of tetracycline (250 mg. three times daily), ammonium chloride (1 gm. three times daily) and postural drainage.

Final admission (thirteen months later). He was followed in the Medical Clinic over the next two months; he soon improved enough to climb two flights of stairs with ease and gained 9 pounds in weight. Repeated x-ray films showed a gradual decrease in the consolidation, with the appearance of numerous cystic bullae above the left second rib, and a residual pneumonitis in the lingula (Fig. 2). Five months after discharge Gantrisin was substituted for tetracycline; three months later he was still expectorating a tablespoonful of sputum daily but was feeling well. For his convenience he was referred from the Medical Clinic to his family doctor. He had continued to do well, with a 30-pound gain in weight on Gantrisin therapy and postural drainage.

Three days before admission cough, dyspnea and fever were ushered in by a shaking chill and an episode of vomiting. Since then he had become progressively more sick. He denied hemoptysis and pain in the chest.

On physical examination the patient appeared acutely ill, cyanotic, dyspneic and dehydrated. The left side of the chest was dull to percussion over the upper half posteriorly and the upper third anteriorly. Bronchial breath sounds, increased fremitus and fine inspiratory rales were heard over the same area. The right side of the chest was about normally resonant, with some coarse inspiratory rhonchi and expiratory groans. The tachycardia was associated with premature beats. A Grade 2 apical systolic murmur was heard. No friction rub was audible. The abdominal examination was noncontributory.

The temperature was 102.4°F., the pulse 132, and the respirations 40. The blood pressure was 130 systolic, 60 diastolic.

Urinalysis was negative. Examination of the blood showed a white-cell count of 1800, with 80 per cent neutrophils, and a hemoglobin of 12.8 gm. per 100 cc. A second white-cell count was 2100. The nonprotein

FIGURE 3. *Roentgenogram of the Chest Taken during the Second Admission, Showing Extensive Involvement of Both Lungs, with a Mottled Pattern Suggesting Multiple Small Areas of Cavitation.*

nitrogen was 68 mg. per 100 cc. The carbon dioxide was 17 milliequiv., the chloride 79 milliequiv., the sodium 108 milliequiv., and the potassium 3.0 milliequiv. per liter, and the pH 7.30. X-ray films of the chest demonstrated a diffuse involvement of the left lung, with a mottled consolidation. Mottled densities were also noted in the right lung, with a sparing of the base and apex (Fig. 3). No fluid or collapse was evident. A sputum culture was reported on the second hospital day as giving an abundant growth of Friedländer's bacillus, *Haemophilus influenzae* and moderate growth of alpha-hemolytic streptococci.

When first admitted to the hospital the patient was placed on oxygen and started on a course of tetra-

cycline; on the second day, chloramphenicol and streptomycin were added. The temperature fell to 100 and 101°F. on the second day. The temperature varied from normal to 100°F., and he had a stable blood pressure and pulse. However, lividity and coldness of the limbs developed, and he died, without other premonitory signs.

Differential Diagnosis

Dr. Victor G. Balboni*: This elderly patient entered the hospital for the first admission with an acute pneumonia of the left upper lobe; Friedländer's bacilli were obtained by culture, and apparently a diagnosis of Friedländer's pneumonia was made. He was treated successfully from the point of view that he recovered from the acute phase of the pneumonia, but what sounds like bronchiectasis of the left upper lobe and lingula later developed. The clinical course after discharge was satisfactory, for he gained weight and was getting along well. Thirteen months later he was readmitted to the hospital with extensive involvement of both lungs; therapy was unsuccessful, and he died.

I should like to try to answer three questions that this case raises. Can the entire clinical course be explained on the basis of Friedländer's infection of the lung? Was some complicating disease present in the lungs such as cancer, tuberculosis or one of the bronchomycoses? What was the nature of the renal lesion that appeared during the final admission? Before proceeding with the discussion I should like to see the x-ray films.

Dr. Joseph Hanelin: These films of the chest extend over the period from the first to the last admission. An extensive consolidative process appears in the left upper lobe, without any loss of volume of the lobe itself (Fig. 1). This is one of the features of Friedländer's pneumonia. The lung is relatively rigid, and there may actually be some expansion of the lobe rather than contraction. Bulging of the major septum, which is present in this case, has been described as fairly characteristic of the disease and is probably related to the overexpansion of the lobe. Very often, in Friedländer's infection, we see multiple cavities, but they are not too well defined here. Five months later the left-upper-lobe lesion has largely disappeared; there are a few linear strands of density that persist (Fig. 2). The right lung has remained clear. On the final admission there is massive involvement of both lungs, predominantly on the left side (Fig. 3). The consolidation has a mottled pattern, which may represent small zones of cavitation, and a similar texture is noted on the right side though here the disease is less extensive.

Dr. Balboni: Can you demonstrate the bullae described in the protocol in these films?

Dr. Hanelin: That may be this area at the left apex. The most impressive finding in the second examination is the suggestion of multiple small cavities, which may be due to diffuse pulmonary necrosis.

Dr. Balboni: Whenever one sees a patient of this age group who has recurrent pulmonary infection, the possibility of cancer of the lung must be considered. This patient, moreover, had been a heavy smoker most of his life. Against the possibility of cancer are the facts that no lesion was seen at bronchoscopy, that the bronchus appeared open in the x-ray examination, and that after the first admission he was quite well and gained 30 pounds. Although with a lung cancer, and an infection that is controlled, a patient may show temporary improvement, I should not expect the improvement to be so great. It is also of interest that no clubbing of the fingers developed. I think I can rule out cancer of the lung.

Could he have had tuberculosis? We know that he had Friedländer's infection of the lung. Why bring in tuberculosis? Tuberculosis has been reported as complicating Friedländer's infection in the lung and is a definite possibility in this case. The protocol does not tell us whether acid-fast stains were made on the sputum during the second admission. Without this information, I can do no more than mention the possibility that tuberculosis developed or became reactivated in a man who had a Friedländer infection in the lung.

About the same can be said for mycotic infections of the lung — there is no evidence from the sputum studies that he had a mycotic infection.

That brings me to Friedländer's pneumonia. Can that explain the clinical course? Friedländer's pneumonia, of course, is a rare form of pneumonia; it occurs primarily in older people, particularly those debilitated by age or by chronic alcoholism. Its onset is somewhat different from that of ordinary pneumococcal pneumonia. It frequently begins, as this man's illness began, with a chronic bronchitis preceding signs and symptoms of pneumonia. Dr. Hanelin pointed out that the x-ray picture at the time of the first admission was characteristic. Friedländer's pneumonia responds poorly to sulfonamides; it responds with variable success to the broad-spectrum antibiotics. Before antibiotic therapy 70 to 80 per cent of the patients died in the acute phase; another 20 to 30 per cent either recovered completely or went on to a chronic stage. The infection in this man apparently went on to develop into bronchiectasis of the right upper lung and lingula, which is one of the accepted methods of advancement of this disease. It is also quite characteristic of chronic Friedländer infection to be accompanied by acute exacerbations, with pneumonic spread. I think that had happened when the patient was admitted for the second time. The low white-cell count is not unusual with acute spread of Friedländer's pneumonia. He had been receiving sulfonamides so, of course, one wonders whether the sulfonamides had depressed the white-cell count. I think it is more probable that the leukopenia was the result of the infection. I believe the clinical

*Assistant physician, Massachusetts General Hospital.

course and death were consistent with an infection due to Friedländer's bacillus.

The slightly elevated nonprotein nitrogen may well be explained on the basis of the dehydration on entry. However, nephritis has recently been reported with pneumonia and confirmed by needle biopsy of the kidneys. This nephritis is characterized primarily by tubular inflammation and degeneration, but there is also some increased cellularity in the glomeruli. Parrish and his co-workers* have reported 3 such cases recently. I think this should be considered a possibility. Another possibility is a renal lesion as the result of the sulfonamides. The absence of any cellular elements in the urine militates against this possibility. I shall choose to explain the renal lesion on the basis of a mild nephritis secondary to the lung infection.

DR. EDWARD B. BENEDICT: I think Dr. Balboni mentioned the bronchoscopic findings as evidence against carcinoma. That is true only to a limited extent, for, as I stated in my bronchoscopic report in this case, "carcinoma beyond the reach of the bronchoscope cannot be excluded."

DR. AUSTIN L. VICKERY: I think a great deal is "written off" in a patient of seventy-eight years who has been "rickety" for a long time. He was seen in Pulmonary Rounds during the first admission after the diagnosis of probable Friedländer pneumonia had been made. Dr. Edward D. Churchill, who was presented the problem of unresolving chronic left-upper-lobe pneumonitis of proved Friedländer-bacillus origin, stated that he probably would have recommended resection of the left upper lobe to prevent the development of an abscess if the patient had been younger. However, in consideration of the patient's years, it was decided to send him home under conservative medical management.

CLINICAL DIAGNOSIS

Pneumonia, due to Friedländer's bacillus.

DR. VICTOR G. BALBONI'S DIAGNOSES

Friedländer's pneumonia.
Nephritis, secondary to lung infection.

*Parrish, A. E., Rubenstein, N. H., and Howe, J. S. Acute renal insufficiency associated with respiratory infections. *Am. J. Med.* 18: 237-242, 1955.

ANATOMICAL DIAGNOSES

Pneumonia, due to Friedländer's bacillus, acute and chronic, with pulmonary fibrosis.
Bronchiectasis.
Cor pulmonale.

PATHOLOGICAL DISCUSSION

DR. VICKERY: Dr. Balboni has given an excellent résumé of the sequence of events in Friedländer's pneumonia. Two things that influence the pathologist at the time he sees lungs at the autopsy table in making a presumptive diagnosis of Friedländer's pneumonia include known pulmonary symptomatology of prolonged chronicity, with x-ray evidence of an unresolved pneumonitis, and a slimy, sticky appearance of the lungs on section — an appearance peculiar to the exudate produced by this organism. Both lungs exhibited extensive involvement by pneumonitis, the combined weight being 2400 gm. The bronchial trees contained thick, tenacious, mucoid pus. In the left lung, the process was more chronic, with fibrosis, fibrous pleuritis, bronchiectasis, emphysema and multiple small abscesses. Throughout the involved area there were fibrous strands between which were thickened abscess compartments filled with polymorphonuclear leukocytes — the typical picture of chronic Friedländer pneumonia. The right lung showed a similar picture, but the process appeared more recent. There was extensive acute pneumonitis, characterized by lysis of alveolar walls, and many small abscesses — a true acute lobar type of pneumonia.

The chronic phase of Friedländer's pneumonia, as Dr. Balboni mentioned, is an infrequent complication or aftermath in the relatively small percentage of patients who recover from their first bout of the infection. It is not uncommon, however, for such a case to go on for several months or over a year before there is an acute exacerbation, often with spread to the opposite lung, terminating in death. This sequence could explain the final episode in this man's illness. It might be mentioned that the patient had cor pulmonale, the wall of the right ventricle measuring 8 mm., which is consistent with the pulmonary fibrosis. We did not find any signficant intrinsic renal disease. The elevated blood nonprotein nitrogen was probably on the basis of dehydration.

The New England Journal of Medicine

Official Organ of
THE MASSACHUSETTS MEDICAL SOCIETY

OWNED BY THE SOCIETY AND
PUBLISHED WEEKLY UNDER THE JURISDICTION OF THE
COMMITTEE ON PUBLICATIONS

Richard M. Smith, M.D., *Chairman*
James P. O'Hare, M.D. — Richard E. Alt, M.D.
Oliver Cope, M.D. — James M. Faulkner, M.D.

Joseph Garland, M.D., EDITOR
ASSOCIATE EDITORS
Thomas H. Lanman, M.D. — Donald Munro, M.D.
Theodore H. Ingalls, M.D.

Robert O'Leary, ASSISTANT EDITOR
Milton C. Paige, Jr., BUSINESS MANAGER

EDITORIAL BOARD
Henry R. Viets, M.D. — Benjamin Castleman, M.D.
Dwight O'Hara, M.D. — J. Englebert Dunphy, M.D.
Fletcher H. Colby, M.D. — Robert W. Buck, M.D.
Robert L. Goodale, M.D. — Herrman L. Blumgart, M.D.
Chester M. Jones, M.D. — Frank N. Allan, M.D.
Harvey R. Morrison, M.D. — Harvey A. Kelly, M.D.
Maxwell Finland, M.D. — Langdon Parsons, M.D.
Vernon P. Williams, M.D. — Mark Ainer, M.D.

MANUSCRIPTS, including references or bibliography, should be typewritten double spaced and submitted as original copy. References should conform to the style of the *Quarterly Cumulative Index Medicus* (listing name and initials of author, title of article, journal, volume number, first and last pages and year), and should be cited numerically in the order in which they appear in the text; the number should be limited to the absolute minimum.

ILLUSTRATIONS are reproduced as half tones and zinc etchings. Photographs must be distinct, and drawings done in black ink on white paper and each properly labeled.

MATERIAL printed in the *New England Journal of Medicine* is covered by copyright. Articles are accepted for consideration with the understanding that they are contributed for publication solely in this journal. The *Journal* does not hold itself responsible for statements made by any contributor.

MATERIAL, other than original articles, should be received not later than noon on Thursday, three weeks before date of publication.

COPY for advertisements is accepted by the advertising committee of the *Journal* on the basis of the apparent quality and usefulness of the product and the manner of its presentation. Proprietary names of pharmaceutical products must be accompanied by the chemical, or generic or official names, and the quantity of all active substances and the recommended dose must be stated. Copy should be factual, conservative and in good taste.

ALTHOUGH it is believed that all advertising material accepted conforms to ethical medical standards, acceptance does not imply endorsement by the *Journal*.

SUBSCRIPTION TERMS: $8.00 per year in advance, postage paid, for the United States (interns and medical students, $5.00 per year); Canada, $9.00 per year (Boston funds); foreign, $10.50 per year. Long-term rates: United States, 2 years $15.00, 3 years $22.00; Canada, 2 years $17.00, 3 years $25.00; foreign, 2 years $20.00, 3 years $29.50.

MICROFILM volumes available to regular subscribers through University Microfilms, 313 N. First Street, Ann Arbor, Michigan.

COMMUNICATIONS should be addressed to the *New England Journal of Medicine*, 8 Fenway, Boston 15, Massachusetts. Telephone KE 6-2094.

CAMERA OBSCURA

EARLY this summer a petition was presented to President Eisenhower urging fundamental changes in the Federal Security Program. Signed by more than 1500 physicians, all of them more or less distinguished in their profession and certainly of unquestionable loyalty to their country and the basic principles of its government, it had as the immediate reason for its presentation the now celebrated case of Dr. John P. Peters, John Slade Ely Professor of Medicine at Yale University.

Dr. Peters, a liberal thinker entitled to all the rights, privileges and protection of loyal citizenship, having twice been investigated and cleared by the Federal Security Program, was later dismissed as special consultant to the Surgeon General — a post that was listed as entirely nonsensitive — because of a "reasonable doubt" regarding his loyalty. Some of the evidence on which he was dismissed was not made known to him, nor was he ever apprised of the identity of his accusers or permitted to face them. Indeed, the identity of only one of this fog of clandestine witnesses was made known even to the Loyalty Review Board that brought in the judgment. The trial was by innuendo, so far as anyone knows, and the verdict secretly arrived at; on June 6 the Supreme Court ruled that the dismissal had been unjust.

Nevertheless a fuse has been lighted that may, if not extinguished, do great damage to that very liberty that inspired the founding of this nation.

The principle on which the petition was based, however, was not the injustice that had been done to an individual with the inescapable defamation of character that accompanies it. It was the employment of a system of investigation and judgment that is not only repugnant to all whose sense of justice is fully developed, but inimical to the very security that it is designed to protect. It is a system well calculated to stifle the "winnowing breeze of freedom" without which science and the arts of peace cannot prosper. Despite the verdict of the Supreme Court in favor of Dr. Peters, strict legality is not at stake in this issue, for the right of dismissal, on whatever grounds, remains with the employing agent. What is at stake is rather a matter of national morality — the right of the accused person to hear the accusations against him, to face his accusers and to appeal to some higher tribunal if the verdict goes against him. What is at stake, perhaps paradoxically, is the security of the country if individual rights can be too far abrogated in its name.

From a practical point of view, it is stated, an impressive number of research grants are now being withheld by the United States Public Health Service from unclassified projects involving no security risks, because of "suspicions" entertained against various scientists. A knowledge of these experiences, according to the President's petitioners, has discouraged

and continues to discourage qualified physicians from engaging in research problems related to the nation's health. Mr. Eisenhower is invited to recall his own words of November 23, 1953:

> In this country, if someone dislikes you or accuses you, he must come up in front, . . . He cannot assassinate you or your character from behind without suffering the penalties an outraged citizenry will inflict.

As phrased by the *New York Times* on March 7, 1955, "the soundest of the foundations of our national tradition of freedom and justice are at stake. And if these are not sound, we have no security and can have none." Acknowledging the necessity of restraints upon liberty, if liberty is to survive, the petition ends on a note struck by Edmund Burke when he said that "it ought to be the constant aim of every wise public council to find out by cautious experiments, and cool rational endeavors, with how little, not how much of this restraint the community can subsist; for liberty is a good to be improved, and not an evil to be lessened."

So long as the country enjoys its present substantial degree of civil liberty and a reasonable prosperity it need never fear a reign of terror. What it can have, if it permits itself to become sufficiently fearful, is a reign of suspicion and petty persecutions by petty bureaucrats.

STUDENTS SHUN SCIENCE COURSES

Medical educators in this country have recently become concerned over the decline in the number of suitable applicants for admission to medical schools; indeed, some schools are already finding it difficult to fill their classes with properly qualified students. This phenomenon appears to be symptomatic of the declining interest of American students in mathematics and in all types of physical and biologic sciences. Moreover, this decline may be expected to become accelerated in the near future because of the increasing deficit of teachers qualified to teach these subjects in the secondary schools.

Recently released figures on the number of teachers of mathematics and the sciences now available and in prospect (*New York Times*, June 19, 1955) have given leading educators and scientists cause for considerable alarm. Half the country's high schools now do not offer courses in chemistry, and even more do not give courses in physics. The percentage of high-school students taking courses in mathematics has dropped to half, and those taking physics to a fifth in the past fifty years. Moreover, many of the courses in mathematics and in the sciences are being taught in these schools by persons who are not qualified.

Among the past year's college graduates, there were 57 per cent fewer men and women qualified to teach these subjects than there were even five years ago, and from among the graduates it is expected to fill only about a third of the 6000 vacancies that are available for science teachers in high schools. The shortage of engineers and other scientific personnel is reflected in the many pages of advertisements that are now appearing in leading newspapers offering lucrative positions to all types of trained scientists and engineers; it was also the subject of a message by the incoming president of Sigma Xi in the *American Scientist*, July, 1955, expressing grave concern and seeking remedies for the situation.

Without doubt the same trend is largely responsible for the declining numbers of persons qualified to enter the medical schools. The tendency in high schools is for increasing numbers of students to take "easy" courses, such as social studies, vocational education and "how-to-live" subjects, while sidetracking the "hard" subjects, such as mathematics, physics and chemistry. This trend is carried over into the colleges, and may be largely responsible for the increasing emphasis that universities and medical schools are placing on the "behavioral" and "social" sciences. This tendency has dangerous potentials for the future of scientific medicine. Moreover, it threatens to weaken the country's position of leadership in science throughout the world and, repugnant as the thought may be, it gives potential enemies an unearned advantage since they are accelerating the rate at which they are producing new engineers and scientists. It is time this danger was realized and the brakes applied to such a development while remedial measures are sought that will stimulate interest in the study and teaching of mathematics and the physical and biologic sciences. Only thus can such a dangerous trend be reversed. This danger and possible remedies through Congressional action were emphasized by Congressman W. Sterling Cole at a meeting of the Mohawk Association of Scientists and Engineers.*

*Cole, W. S. Science and statecraft. *Science* 121:885-887, 1955.

EXOCRINE RESEARCH FOUNDATION

With the assurance that their addition to the growing list of medical foundations will not enter the present furious competition for popular financial support, the administrative officers of the brand-new Children's Exocrine Research Foundation announce the creation, under impeccable auspices, of this newest scientific establishment. The Foundation has been organized for the encouragement and support of investigation into mucoviscidosis — better, although still not widely known, as cystic fibrosis of the pancreas.

This congenital disease, until recently considered as practically universally fatal, affects the glands of external secretion, causing an abnormal and obstructive flow of viscid mucus. Among its most serious manifestations are obstruction of the pulmonary bronchioles and of the excretory ducts of the pancreas. Identified as a distinct disease as recently as 1938 and still generally believed to be a rare condition, mucoviscidosis is now said to have an incidence of 1 case in every 600 births. Applications for research grants,

it is announced, may be made by communicating with the Foundation headquarters at 2300 Westmoreland Street, Philadelphia.

Although virtually pledged not to make public solicitation for funds, the Foundation is intended nevertheless to carry on the most important function of foundations—to obtain financial resources—in this case from other foundations and interested givers, and to allocate them to research workers interested in the diseases of the exocrine system.

The laying down of still another foundation in addition to the impressive number of such establishments that already exist adds a little more complexity to the current problem of treating disease and carrying on research. With the best wishes in the world for the success of this new venture into divisive science one may still wonder if the increasing tendency of learned investigators to concern themselves more and more obsessively with less and less general subjects is the most effective way of promoting science and human welfare as a whole.

The great foundations that employ their vast resources in the aid of a number of diverse enterprises represent an indispensable source of help and encouragement to science and humanity in general. Progress today would be at a loss without them and would be dependent on public grants and the excess profits of industry to an even greater degree than is now the case.

Admittedly, special grants for specific purposes have been and will continue to be an orthodox method of financing research. A word of caution may nevertheless be in order before the fields in which men labor become so restricted as to shut off the broad view completely and to react unfavorably on each other in the vital matter of pecuniary support.

GAMMA GLOBULIN IN POLIOMYELITIS PROPHYLAXIS

In view of the fact that the National Foundation for Infantile Paralysis has available an amount of gamma globulin first intended for community or group prophylaxis, the Massachusetts Polio Advisory Committee met on July 19 to consider its possible use. The results of the Committee's deliberations were based on the meager evidence that mass inoculation, when carried out in the early stages of a community outbreak, may prevent paralytic poliomyelitis in a small number of cases, and the lack of evidence that gamma globulin has any effect in stopping an epidemic already in progress.

Local health officers have therefore been advised that they may consult with the Department of Public Health in determining whether local conditions indicate the use of the globulin, which, if the decision is favorable, may be requested through the Department. On July 28 it was announced that the Foundation now has gamma globulin for individual use or for family or household contacts.

Milk an Article of Food, not a mere Beverage. — *This has been determined legally the other day by the Court of Cassation in Paris, and its decision is in accordance with sound physiological principles.*

Boston M. & S. J., *August 16, 1855*

MASSACHUSETTS MEDICAL SOCIETY

COMMITTEE ON MATERNAL WELFARE

Pulmonary Embolism

A twenty-eight-year-old gravida I, para 0, with an uneventful prenatal course, was admitted at term and in false labor with membranes intact. The blood pressure was 150 systolic, 70 diastolic; the temperature was 100.8°F., and the pulse 132. She was discharged, but spontaneous labor ensued and after twelve hours she re-entered the hospital with the cervix fully dilated and the vertex on the perineum. Under spinal anesthesia a living infant was delivered by low forceps and a right mediolateral episiotomy. On the following day the patient's temperature was 103°F., with suprapubic and right-costovertebral-angle tenderness. Catheterized urine showed clumps of pus, *Escherichia coli, Staphylococcus albus* and monilia. A film of the chest was normal; the white-cell count was 16,350.

Treatment consisted of chlortetracycline, 250 mg. every six hours, forced fluids, absolute bed rest and aspirin. After twenty-four hours urinary symptoms subsided, but the temperature showed daily elevations gradually diminishing for a week. The abdomen was slightly distended with lower-quadrant tenderness on both sides and foul lochia but no costovertebral-angle tenderness. The patient was allowed out of bed after seven days, and chlortetracycline was discontinued on the following day. On the twelfth day the episiotomy, which had broken down, was resutured under Pentothal Sodium anesthesia. On the thirteenth day, in the bathroom, she was suddenly seized with weakness and dizziness. When seen a few minutes later she was cyanotic and complained of abdominal pain and lack of air. The blood pressure was unobtainable; the pulse (apical) was about 120, and the skin was cool and dry. In the next few minutes she became unconscious, without respirations or pulse despite the usual stimulants and artificial respiration, and died. There was no autopsy.

The case was classified as nonpreventable, the cause of death being presumably pulmonary embolism. This was undoubtedly aggravated, if not caused, by pelvic sepsis. The source of this infection may have been related to the delay in returning for a second admission. An un-named house officer had serious sus-

picions regarding pelvic sepsis and noted foul lochia after the apparent recovery from pyelitis, but unfortunately his apprehensions were not shared by those in authority; whether the patient might have had a fatal embolism anyway is, of course, conjectural. Certainly, the infection should have been more vigorously combated.

JOHN FIGGIS JEWETT, M.D.
Chairman

MASSACHUSETTS DEPARTMENT OF PUBLIC HEALTH

LABORATORIES APPROVED FOR STANDARD SEROLOGIC TESTS FOR SYPHILIS

This year 44 laboratories have been approved for performance of one or more of the standard diagnostic tests for syphilis. Five laboratories not on last year's list have been added, and 3 laboratories on last year's list omitted.

Legally, only these 44 laboratories and the Department of Public Health Wassermann Laboratory may perform the premarital and prenatal blood tests prescribed by law in this state. The Wassermann Laboratory, 281 South Street, Jamaica Plain, is the only laboratory in Massachusetts whose reports are recognized in other states for premarital purposes.

This is the first year that approval for the Venereal Disease Research Laboratory test has been requested. One laboratory is approved for this test. Most of the approved laboratories hold approval for the standard blood Hinton test. The Kahn, Kline, Mazzini and Wassermann tests are also approved for 1 laboratory each.

The laboratories approved for the tests required by law are as follows:

Attleboro:
  Sturdy Memorial Hospital
Boston:
  Boston Dispensary
  Boston Health Department
  Commonwealth Clinical Laboratory
  Haynes Memorial Hospital
  Leary Laboratory
  Massachusetts General Hospital
  Massachusetts Memorial Hospital, Serology Laboratory
Brockton:
  Brockton Health Department
Fall River:
  St. Anne's Hospital
  Union Hospital
Fitchburg:
  Burbank Hospital
Framingham:
  Framingham Union Hospital
Gardner:
  Henry Heywood Memorial Hospital
Great Barrington:
  Fairview Hospital
Greenfield:
  Franklin County Public Hospital
Haverhill:
  Hale Hospital
Holyoke:
  Holyoke Hospital
  Providence Hospital
Lawrence:
  Lawrence General Hospital
Lowell:
  Lowell General Hospital
  St. John's Hospital
Ludlow:
  Ludlow Hospital
Montague:
  Farren Memorial Hospital
New Bedford:
  Burt Laboratory
  Professional Laboratory
  St. Luke's Hospital
Newton:
  Newton-Wellesley Hospital
North Adams:
  North Adams Hospital
Norwood:
  Norwood Clinical Laboratory
Pittsfield:
  Hillcrest Hospital
  Pittsfield General Hospital
  St. Luke's Hospital
Quincy:
  Quincy City Hospital
Salem:
  Salem Hospital
Springfield:
  Mercy Hospital
  Springfield Hospital
Stoneham:
  New England Sanitarium and Hospital
Taunton:
  Morton Hospital
Tewksbury:
  Tewksbury State Hospital and Infirmary
Waltham:
  Waltham Hospital
Worcester:
  St. Vincent Hospital
  Hahnemann Hospital
  Health Department Laboratory

COMMUNICABLE DISEASES IN MASSACHUSETTS FOR JUNE, 1955

RÉSUMÉ

Disease	June 1955	June 1954	Seven-Year Median
Chancroid	3	1	4
Chicken pox	1870	1264	1410
Diphtheria	0	1	12
Dog bite	1789	2044	1597
Dysentery, bacillary	5	15	5
Encephalitis, infectious	2	6	6
German measles	397	1203	665
Gonorrhea	171	178	178
Granuloma inguinale	0	0	0
Hepatitis, infectious	74	93	9*
Lymphogranuloma venereum	1	0	1
Malaria	0	1	1
Measles	1706	4906	2963
Meningitis, meningococcal	3	6	6
Meningitis, Pfeiffer bacillus	1	2	5
Meningitis, pneumococcal	0	6	3
Meningitis, staphylococcal	0	0	0
Meningitis, streptococcal	0	0	0
Meningitis, undetermined	6	8	4
Mumps	851	2177	1403
Poliomyelitis	8	9	6
Salmonellosis	35	20	8
Scarlet fever	692	364	364
Syphilis	150	224	176
Trichinosis	2	4	2
Tuberculosis, pulmonary	163	179	186
Tuberculosis, other forms	11	10	12
Typhoid fever	1	3	2
Undulant fever	2	1	2
Whooping cough	116	141	141

*Six-year median.

COMMENT

Diseases below the seven-year median were diphtheria, German measles, measles, mumps and whooping cough.

No cases of diphtheria were reported during the month of June. The total for the first six months of this year is 14, the lowest figure for this period in the history of the State.

Last month German measles registered the lowest figure for June since 1948.

Diseases above the seven-year median were chicken pox, infectious hepatitis, poliomyelitis, salmonellosis and scarlet fever.

Last month salmonellosis was at the highest level for June since 1946, and scarlet fever was at the highest level for this month since 1948.

GEOGRAPHIC DISTRIBUTION OF CERTAIN DISEASES

The following diseases were reported from the communities named:

Dysentery, bacillary: Danvers, 1; Hamilton, 3; Waltham, 1; total, 5.

Encephalitis, infectious: New Bedford, 1; Westfield, 1; total, 2.

Hepatitis, infectious: Amesbury, 1; Arlington, 1; Boston, 8; Cambridge, 3; Chelsea Naval Hospital, 1; Dartmouth, 1; Dracut, 1; East Bridgewater, 1; Fall River, 5; Fort

Devens, 1; Haverhill, 3; Hingham, 3; Holyoke, 2; Hopedale, 1; Lowell, 5; Lynn, 1; Lynnfield, 1; Malden, 2; Milford, 3; Needham, 4; Newton, 4; Norwood, 1; Pittsfield, 2; Provincetown, 1; Revere, 2; Somerville, 1; Springfield, 7; Waltham, 2; Westfield, 3; Weston, 1; Wrentham, 2; total, 74.

Lymphocytic choriomeningitis: New Bedford, 1.

Meningitis, meningococcal: Boston, 1; Fall River, 1; Weymouth, 1; total, 3.

Meningitis, Pfeiffer bacillus: Quincy, 1.

Meningitis, mumps: Framingham, 1; Medford, 1; Stoughton, 1; total, 3.

Meningitis, undetermined: Hamilton, 1; Hopedale, 1; Pepperell, 1; Webster, 1; Wellesley, 1; Worcester, 1; total, 6.

Poliomyelitis: Boston, 5; Lowell, 1; Lynn, 1; Salem, 1; total, 8.

Rocky Mountain spotted fever: Bridgewater, 1; Chilmark, 2; total, 3.

Salmonellosis: Andover, 1; Arlington, 2; Ashland, 1; Bernardston, 1; Beverly, 1; Billerica, 2; Boston, 4; Brookline, 2; Everett, 1; Fall River, 1; Greenfield, 1; Hamilton, 2; Lynn, 1; Malden, 1; Natick, 2; Newton, 6; Raynham, 1; Revere, 1; Salem, 1; Springfield, 2; Woburn, 1; total, 35.

Trichinosis: Boston, 1; Watertown, 1; total, 2.

Tularemia: Halifax, 1.

Typhoid fever: Norwood, 1.

Undulant fever: Holyoke, 1; Wilmington, 1; total, 2.

CORRESPONDENCE

To the Editor: James Mann, M.D., director of clinical psychiatry and research at the Boston State Hospital, has been granted a year's leave of absence beginning September 1, 1955, to accept an invitation to serve as acting director of the Department of Psychiatry at the Hebrew University-Hadassah Medical School in Jerusalem. Dr. Mann, who is also assistant professor of psychiatry at Boston University School of Medicine, succeeds Dr. Milton Rosenbaum, of the University of Cincinnati, who has been the acting director of the Medical School in Jerusalem for the past year.

Dr. Mann plans to return to his post at the Boston State Hospital after his year abroad.

WALTER E. BARTON, M.D.
Superintendent
Boston State Hospital

Boston

ON FLUID BALANCE AND OTHER TOPICS

To the Editor: Certain medical practices of the last decades of the nineteenth century, as observed by a layman, may interest your readers. When I had my bout with measles I was put to bed in the warmest room in the house in mid-July and covered with extra blankets. The windows were closed, the blinds drawn, and the curtains lowered. Not over a glass of water was allowed in one day. I was taken care of by an old crone, whose specialty was measles and who was always called in instead of a doctor. I suffered in this artificial hell for over two weeks and made a good recovery. All feverish patients, including those with typhoid fever, were given no water or a minute quantity during the course of the fever. This was approved treatment by the best medical authority.

I remember hearing old ladies talking about the efficacy of moldy bread for that "run-down" condition.

The following is an interesting example of preventive medicine as practiced without any scientific understanding of its physiologic basis. Heat prostrations in the hay fields in July were not uncommon. I remember well a case of an overheated farmer who drank icewater and was dead in a few minutes. However, most people knew better, and it was common practice in the hay field to drink "switchel." The origin of the word and the spelling is unknown to me and probably uncertain. Switchel is a decoction of water, molasses, vinegar and ground ginger. It was reasonably cool because it was kept under a haycock in the field in jugs that were frequently replenished from the house. The workers drank copiously of this liquid and perspired freely. It was believed to be a safeguard against heat prostration and shock, and experienced haymakers who drank it rarely had any difficulty. Sometimes, if it was possible to find a spring or brook nearby, the farmer held his hands and arms in the water for five or ten minutes to cool his blood.

With other boys of my age I was on a fishing trip deep in the woods when I accidentally cut a deep gash in my leg with an axe. The wound bled, and I scraped some fir balsam from a tree and filled the cut completely and tied it up with a rag. The wound healed quickly and completely, leaving only the trace of a scar. I did the same thing on another occasion, using fir balsam, and can find no trace now even of a scar.

JOHN H. FULLER

Eaton, New Hampshire

A PROTEST

To the Editor: I wish to protest against the publication of the article entitled "Iridectomy — a Century of Progress," published in the June 9 issue of the *Journal*. This article contains nothing new and nothing old that needs reiteration, and ends with a statement that is untrue — namely, "but Graefe's procedure has survived a full century as the preferred treatment of acute congestive glaucoma." As a matter of fact, the preferred operative treatment for this condition is now simply the making of a small peripheral hole in the iris.

F. H. VERHOEFF, M.D.

Boston

Note: The item to which Dr. Verhoeff takes exception was not intended as a scientific contribution but as a historical reference to a contribution made just a century ago. —ED.

NONCLINICAL NOTES

ALVARENGA PRIZE

The College of Physicians of Philadelphia awarded the Alvarenga Prize for 1955 to Dr. Charles H. Rammelkamp for outstanding work in the field of streptococcal infections, particularly in relation to rheumatic fever and nephritis.

The Alvarenga Prize was established by the will of Pedro Francisco DaCosta Alvarenga, of Lisbon, Portugal, an associate fellow of the College of Physicians of Philadelphia, to be awarded annually on the anniversary of the death of the testator, July 14, 1883.

HONORARY DEGREE FOR DR. VERHOEFF

Dr. F. H. Verhoeff, emeritus professor of ophthalmic research at Harvard and consulting chief of ophthalmology at the Massachusetts Eye and Ear Infirmary, was awarded the honorary degree of Doctor of Science by the University of Louisville, June 5, 1955. He received the degree of LL.D. from Johns Hopkins University in 1953.

NOTICES

ANNOUNCEMENTS

Dr. Warren Bennett announces the opening of his offices for the practice of internal medicine at 606 Main Street, Malden, and at 1152 Beacon Street, Brookline, Massachusetts.

Dr. William A. Richards announces the opening of his office for the practice of internal medicine at 19 Appleton Street, Waltham, Massachusetts.

MASSACHUSETTS EYE AND EAR INFIRMARY FELLOWSHIP

The Massachusetts Lions Eye Research Fund has created the E. B. Dunphy Fellowship for Eye Research. The Fellowship will carry an annual stipend of $5,000 and will be awarded on a yearly basis. Anyone may apply, but the research must be conducted in Massachusetts. Further information may be obtained from Dr. E. B. Dunphy, 243 Charles Street, Boston, Massachusetts.

RESEARCH ON MUSCULAR FUNCTION

Information regarding results of research on muscular function is requested by Drs. Endre Szirmai and Eörs Bajusz, of Budapest. Reprints of articles on this subject will be gratefully received by Dr. Szirmai, at VII., Madách-u. 12, or Dr. Bajusz, at V., Arany J.—.-u.11, Budapest, Hungary.

AMERICAN PSYCHOSOMATIC SOCIETY

The thirteenth annual meeting of the American Psychosomatic Society will be held at the Sheraton Plaza Hotel in Boston, March 24 and 25, 1956. Titles and abstracts of papers for consideration for the program should be received no later than December 1, 1955. The time allotted for the presentation of each paper will be twenty minutes. Abstracts should be submitted in sextuplicate to the Chairman, 551 Madison Avenue, New York 22, New York.

HEART-DISEASE SEMINAR

Two seminars on heart disease will be presented by the Vermont Heart Association, in co-operation with the University of Vermont College of Medicine, September 14 through 17, in Burlington, Vermont. The seminar on functional and degenerative heart disease will be given by Dr. W. Raab on September 14 and 15. The seminar on electrocardiographic diagnosis of atrial and ventricular hypertrophy and strain will be given by Drs. E. Lepeschkin and B. Surawicz, on September 16 and 17. Drs. R. P. Grant and E. Cabrera will be the guest speakers. Further information may be obtained from Drs. Raab or Lepeschkin, Division of Experimental Medicine, University of Vermont College of Medicine, Burlington, Vermont.

SOCIETY MEETINGS AND CONFERENCES

AUGUST and SEPTEMBER. Beth Israel Hospital Course. Page 509, issue of March 24.

AUGUST 22 and AUGUST 23. Consultation Clinics for Crippled Children in Massachusetts. Page 1099, issue of June 23.

AUGUST 28–SEPTEMBER 2. American Congress of Physical Medicine and Rehabilitation. Page 157, issue of January 27.

AUGUST 30 and 31 and SEPTEMBER 1. New England Health Institute. Page 1010, issue of June 9.

SEPTEMBER 12–21, DECEMBER 5–14, 1955, JANUARY 30–FEBRUARY 8, MARCH 19–28 and JUNE 4–13, 1956. Army Medical Service Postgraduate Course. Page 84, issue of July 14.

SEPTEMBER 14–17. Heart-Disease Seminar, Notice above.

SEPTEMBER 21. Essex North District Medical Society. Page 208, issue of August 4.

SEPTEMBER 21. New Jersey Neuro-Psychiatric Institute. Page 208, issue of August 4.

SEPTEMBER 30–OCTOBER 1. American Medical Writers' Association. Page 118, issue of July 21.

OCTOBER 1 and 2 and 3–6. American Academy of Pediatrics. Page 118, issue of July 21.

OCTOBER 3. Arthritis and Rheumatism Foundation. Page 208, issue of August 4.

OCTOBER 6–8. Academy of Psychosomatic Medicine. Page 509, issue of March 24.

OCTOBER 10–21. New York Academy of Medicine. Graduate Fortnight. Page 84, issue of July 14.

OCTOBER 19 and DECEMBER 14, 1955 and FEBRUARY 15, MARCH 28 and APRIL 18, 1956. Greater Boston Medical Society. Page 208, issue of August 4.

OCTOBER 22–26. American Heart Association. Scientific Session. Page 605, issue of April 7.

OCTOBER 23–27. American Institute of Dental Medicine. Page 414, issue of March 10.

OCTOBER 26 and NOVEMBER 30, 1955 and JANUARY 25, MARCH 21 and APRIL 26, 1956. Phi Delta Epsilon Fraternity Graduate Club Program. Page 118, issue of July 21.

OCTOBER 27–29. Congress of Neurological Surgeons. Page 208, issue of August 4.

NOVEMBER 1–3. Henry Ford Hospital Symposium on Enzymes. Page 920, issue of May 26.

NOVEMBER 6–13. Second International Congress of Allergology. Page 157, issue of January 27.

NOVEMBER 7–9. Association of Military Surgeons of the United States. Page 118, issue of July 21.

NOVEMBER 11 and 12. Inter-Society Cytology Council. Page 1056, issue of June 16.

NOVEMBER 14 and 25. Course in Laboratory Diagnosis of Tuberculosis. Page 1102, issue of June 23.

NOVEMBER 19–21. American Association of Blood Banks. 8th Annual Meeting. Palmer House, Chicago, Illinois.

NOVEMBER 28–DECEMBER 2. Interim Session of the American Medical Association, Boston.

MARCH 24 and 25, 1956. American Psychosomatic Society. Notice above.

CALENDAR FOR THE WEEK BEGINNING THURSDAY, AUGUST 18

THURSDAY, AUGUST 18

*8:00–8:45 a.m. Case Presentations. Joslin Clinic. Joslin Auditorium, New England Deaconess Hospital.
*9:00–10:00 a.m. Surgical Rounds. Sherman Auditorium, Beth Israel Hospital.
*9:00–10:00 a.m. Arthritis Grand Rounds. Robert Breck Brigham Hospital.
*10:00–11:00 a.m. Combined Medical-Surgical Rounds. Sherman Auditorium, Beth Israel Hospital.
10:30–11:15 a.m. Lecture on Diabetes for Doctors and Patients by a Member of the Joslin Clinic. Joslin Auditorium, New England Deaconess Hospital.
*11:00 a.m.–12:00 m. Thoracic Conference. Circuit Grand Rounds. Medical and Surgical Thoracic Problems. Drs. Dwight E. Harken, Hugh E. Wilson and Warren J. Taylor. Main Amphitheater, Peter Bent Brigham Hospital.
*11:00 a.m.–12:00 m. Medical Staff Conference. Sherman Auditorium, Beth Israel Hospital.
*11:00 a.m.–12:30 p.m. Hand Clinic (Physical Medicine and Rehabilitation Service). Boston City Hospital.
*12:15–1:15 p.m. Tumor Clinic. Dr. T. W. Botsford. Amphitheater, Peter Bent Brigham Hospital.

FRIDAY, AUGUST 19

*8:00–8:45 a.m. Case Presentations. Joslin Clinic. Joslin Auditorium, New England Deaconess Hospital.
*9:30–11:30 a.m. Medical and Surgical Grand Rounds. Drs. George W. Thorn and Francis D. Moore. Main Amphitheater, Peter Bent Brigham Hospital.
*10:00 a.m. Tuberculosis Surgical Clinic. South End Health Unit, 57 East Concord Street.
10:30–11:15 a.m. Lecture on Diabetes for Doctors and Patients by a Member of the Joslin Clinic. Joslin Auditorium, New England Deaconess Hospital.
*1:30 p.m. Fertility and Endocrine Clinic. Free Hospital for Women, Brookline.
*1:30 p.m. Tumor Clinic. Mount Auburn Hospital, Cambridge.
*4:00–10:00 p.m. Alcoholism Clinic. By appointment. Washingtonian Hospital, 41 Morton Street, Jamaica Plain.

SATURDAY, AUGUST 20

*8:00–8:45 a.m. Case Presentations. Joslin Clinic. Joslin Auditorium, New England Deaconess Hospital.
10:30–11:15 a.m. Lecture on Diabetes for Doctors and Patients by a Member of the Joslin Clinic. Joslin Auditorium, New England Deaconess Hospital.

MONDAY, AUGUST 22

*8:00–8:45 a.m. Case Presentations. Joslin Clinic. Joslin Auditorium, New England Deaconess Hospital.
*8:00–9:00 a.m. Medical and Surgical Clinic on Diabetic Problems. New England Deaconess Hospital.
*8:30–9:30 a.m. Clinic by Entire Surgical Staff and Anesthesia Staff. New Cheever Amphitheater, Dowling Building, Boston City Hospital.
10:30–11:15 a.m. Lecture on Diabetes for Doctors and Patients by a Member of the Joslin Clinic. Joslin Auditorium, New England Deaconess Hospital.
*12:15–1:15 p.m. Clinicopathological Conference. Main Amphitheater, Peter Bent Brigham Hospital.
*1:00 p.m. Alcoholism Clinic. Peter Bent Brigham Hospital.
*4:00 p.m. Clinicopathological Conference. Pathology Conference Room, Beth Israel Hospital.
*4:00–5:30 p.m. Anesthesiology Conference. Surgical Conference Room, Peter Bent Brigham Hospital.
*5:00–6:30 p.m. Anesthesia Group of the Lahey Clinic. Joslin Auditorium, New England Deaconess Hospital.

TUESDAY, AUGUST 23

*8:00–8:45 a.m. Case Presentations. Joslin Clinic. Joslin Auditorium, New England Deaconess Hospital.
*9:00 a.m. Geriatrics Clinic. Peter Bent Brigham Hospital.
10:30–11:15 a.m. Lecture on Diabetes for Doctors and Patients by a Member of the Joslin Clinic. Joslin Auditorium, New England Deaconess Hospital.
*12:15–1:15 p.m. X-Ray Conference. Dr. Merrill Sosman. Main Amphitheater, Peter Bent Brigham Hospital.
12:30–1:30 p.m. Medical Journal Club. Joslin Clinic. (Cafeteria) New England Deaconess Hospital.
*5:00–6:00 p.m. Service Meeting followed by Clinical Conference (Medical, Surgical, Obstetrical). Faulkner Hospital.

WEDNESDAY, AUGUST 24

*8:00–8:45 a.m. Case Presentations. Joslin Clinic. Joslin Auditorium, New England Deaconess Hospital.
*9:00–10:00 a.m. Surgical Grand Rounds. Massachusetts Memorial Hospitals.
10:30–11:15 a.m. Lecture on Diabetes for Doctors and Patients by a Member of the Joslin Clinic. Joslin Auditorium, New England Deaconess Hospital.
*11:00 a.m. Boston State Hospital Psychiatry Seminar. Reception Building Auditorium, 591 Morton Street, Dorchester.
*11:00 a.m. Orthopedic Grand Rounds. Bigelow Amphitheater, White 314, Massachusetts General Hospital.
*12:00 m.–1:00 p.m. Pediatric Clinicopathological Conference. Jimmy Fund Building, Children's Medical Center, 35 Binney Street.
*12:00 m.–1:00 p.m. Roentgen Diagnostic Conference. 5th-floor teaching unit, Beth Israel Hospital.
*12:15 p.m. Vascular Rounds. Drs. Edward A. Edwards and Chilton Crane. D-Main, Peter Bent Brigham Hospital.
*12:30 p.m. Weekly Pathological Meeting. Joslin Auditorium, New England Deaconess Hospital.
*12:30–1:30 p.m. Weekly Staff Review of Autopsies. Dr. William A. Meissner. Joslin Auditorium, New England Deaconess Hospital.
*1:00 p.m. Alcoholism Clinic. Peter Bent Brigham Hospital.
*1:00 p.m. Massachusetts General Hospital Hand Clinic. The Clinics of the Massachusetts General Hospital.
*2:00 p.m. Rectal Clinic. Peter Bent Brigham Hospital.
*4:00–5:30 p.m. Fracture Lecture. Boston City Hospital.
*4:00–6:00 p.m. Overholt Thoracic Conference. Joslin Auditorium, New England Deaconess Hospital.
*6:00 p.m. Alcoholism Clinic. Peter Bent Brigham Hospital.
*7:30–9:30 p.m. Lahey Clinic Lecture. Joslin Auditorium, New England Deaconess Hospital.

*Open to the medical profession.